

## STRATAFIX™ Symmetric PDS™ Plus Knotless Tissue Control Devices

# Recommended Closure Technique

STRATAFIX Symmetric PDS Plus Devices eliminate the need for intracorporeal knot tying to anchor the device at the beginning and end of the closure—for greater ease of use in both open and minimally invasive procedures, including robot-assisted.<sup>1</sup>

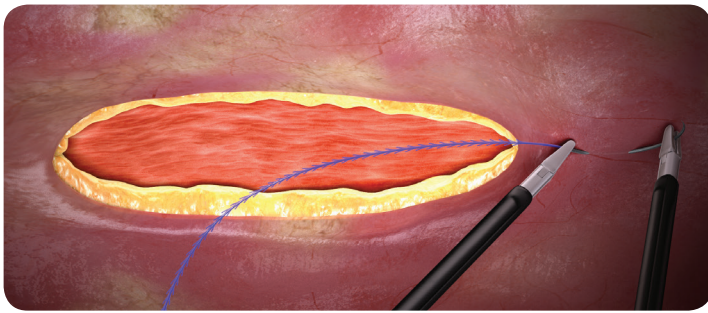
**The Instructions for Use (IFU) recommends a closure technique designed to:**

- Isolate the fixation tab away from the incision
- Minimise tension
- Ensure a strong, dependable closure

### Seating the fixation tab

There are two options for where to seat the fixation tab when initiating closure, and either option may be used regardless of procedure type (minimally invasive or open):

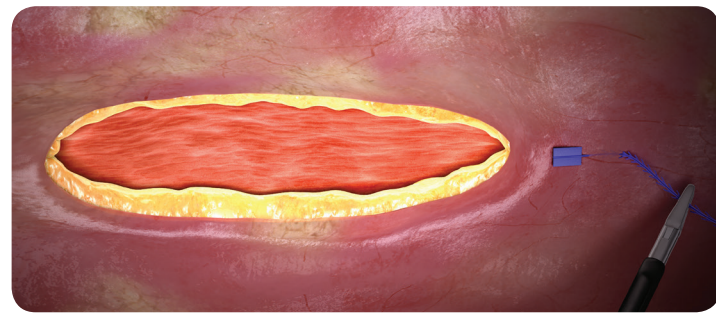
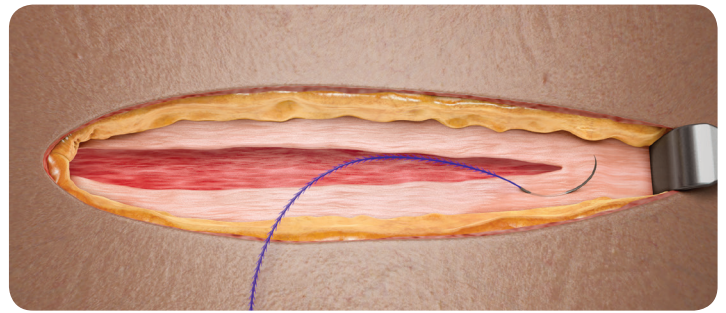
#### Above the apex of the incision



**FIG 1A**

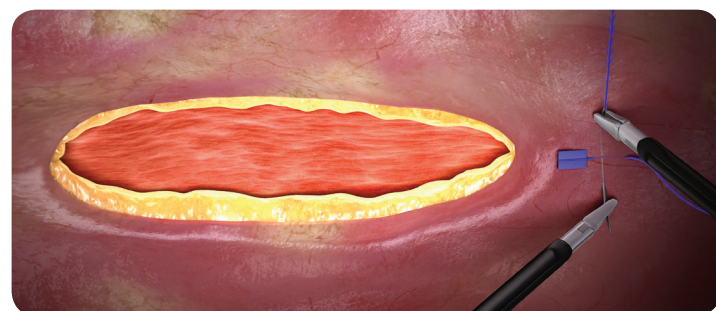
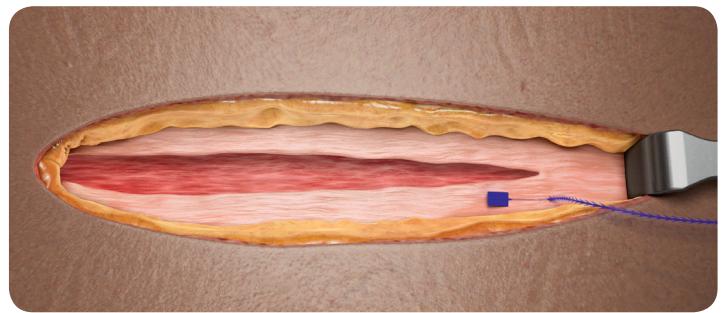
Take the first pass directly **above** or **adjacent** to the apex in a direction away from the incision.

#### Adjacent to the apex of the incision



**FIG 1B**

Pull the device through the tissue to gently seat the fixation tab. The fixation tab should be seated above the tissue plane and be visible. Do not exert additional force on the fixation tab or device.



**FIG 1C**

Moving toward the apex of the incision, take a pass in the intact tissue perpendicular to the initial pass. Multiple passes are acceptable. Pull gently on the device to take up any slack.

## Closing the incision

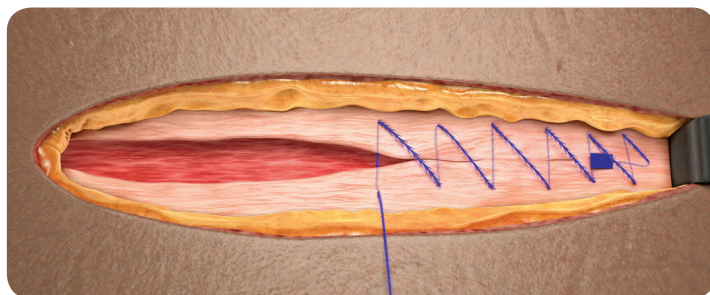
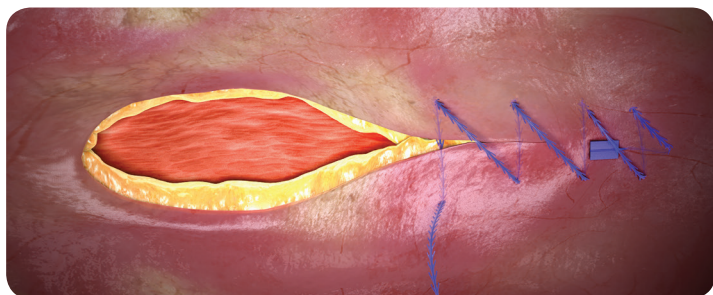


FIG 2

Proceed with a continuous closure pattern to close the incision, taking apposing bites on either side of the wound in standard fashion. To achieve the desired approximation and tension, gently pull on the device with each tissue passage. Continue approximating along the length of the incision, taking care not to overtighten the device. Retain approximately 3" (8 cm) of the device for completing reverse stitching to secure the terminal end.

## Completing the closure

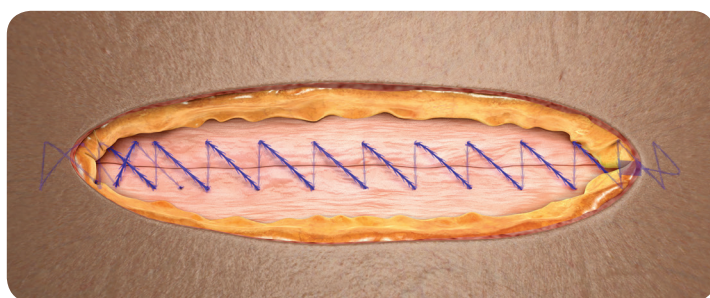
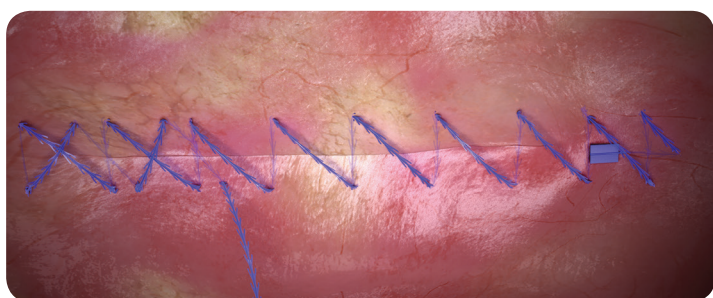


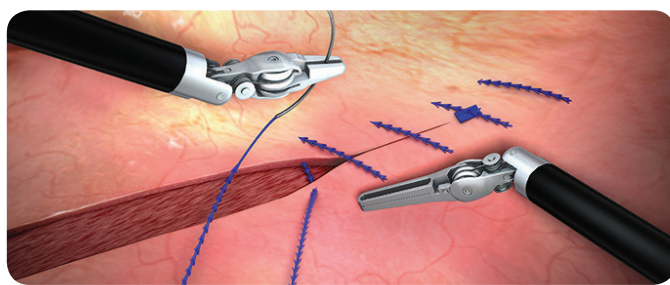
FIG 3

To complete and secure the closure, **take 2 passes in the reverse direction across the incision**. Then, gently pull on the free end of the device and cut flush with the surface of the tissue. Closure is complete.

## Get more with STRATAFIX™ Knotless Tissue Control Devices<sup>2-10</sup>

- More security\*
- More consistency\*
- More efficiency\*

\*Than traditional sutures



**For complete indications, contraindications, warnings, precautions, and adverse reactions, please reference full package insert.**

### References

1. STRATAFIX™ Symmetric PDS™ Plus Knotless Tissue Control Device Instructions for Use. Ethicon, Inc. 2. Perkins J, Nawrocki J. Ethicon Technical Memo. STRATAFIX Symmetric PDS Plus - Mass of Size 1 Fixation Tab vs. Size 1 PDS Suture Knot Tower. 10-31-2012. Ethicon, Inc. 3. Nonnenmann H. Ethicon Performance Evaluation Memo AST-2012-0510. Performance Testing of STRATAFIX Symmetric Size 2-0 suture device for Tissue Holding Strength with an Incision Defect to Measure Gapping. Dated December 3, 2012. Ethicon, Inc. 4. Nonnenmann H. AST-2013-0056 Performance Testing of STRATAFIX Symmetric PDS Size 2-0 suture device for Tissue Holding Strength with Multiple Incision Defects to Measure Gapping. Ethicon, Inc. 5. Moran ME, Marsh C, Perrotti M. Bidirectional-barbed sutured knotless running anastomosis v classic Van Velthoven suturing in a model system. *J Endourol.* 2007;21(10):1175-1178. 6. Vakil JJ, O'Reilly MP, Sutter EG, Mears SC, Belkoff SM, Khanuja HS. Knee arthroscopy repair with a continuous barbed suture: a biomechanical study. *J Arthroplasty.* 2011;26(5):710-713. 7. Eickmann T, Quane E. Total knee arthroplasty closure with barbed sutures. *J Knee Surg.* 2010;23(3):163-167. 8. Einarsson JI, Chavan NR, Suzuki Y, Jonsdottir G, Vellinga TT, Greenberg JA. Use of bidirectional barbed suture in laparoscopic myomectomy: evaluation of perioperative outcomes, safety, and efficacy. *J Minim Invasive Gynecol.* 2011;18(1):92-95. 9. Levine BR, Ting N, Della Valle CJ. Use of a barbed suture in the closure of hip and knee arthroplasty wounds. *Orthopedics.* 2011;34(9):e473-e475. doi: 10.3928/01477447-20110714-35. 10. Overaker D. Ethicon study AST-2012-0331. Tissue gapping under tension of porcine cadaveric skin incisions closed with Stratafix Spiral in comparison to Monocryl in both interrupted and continuous stitching patterns. Approved on August 24, 2012. Ethicon, Inc.