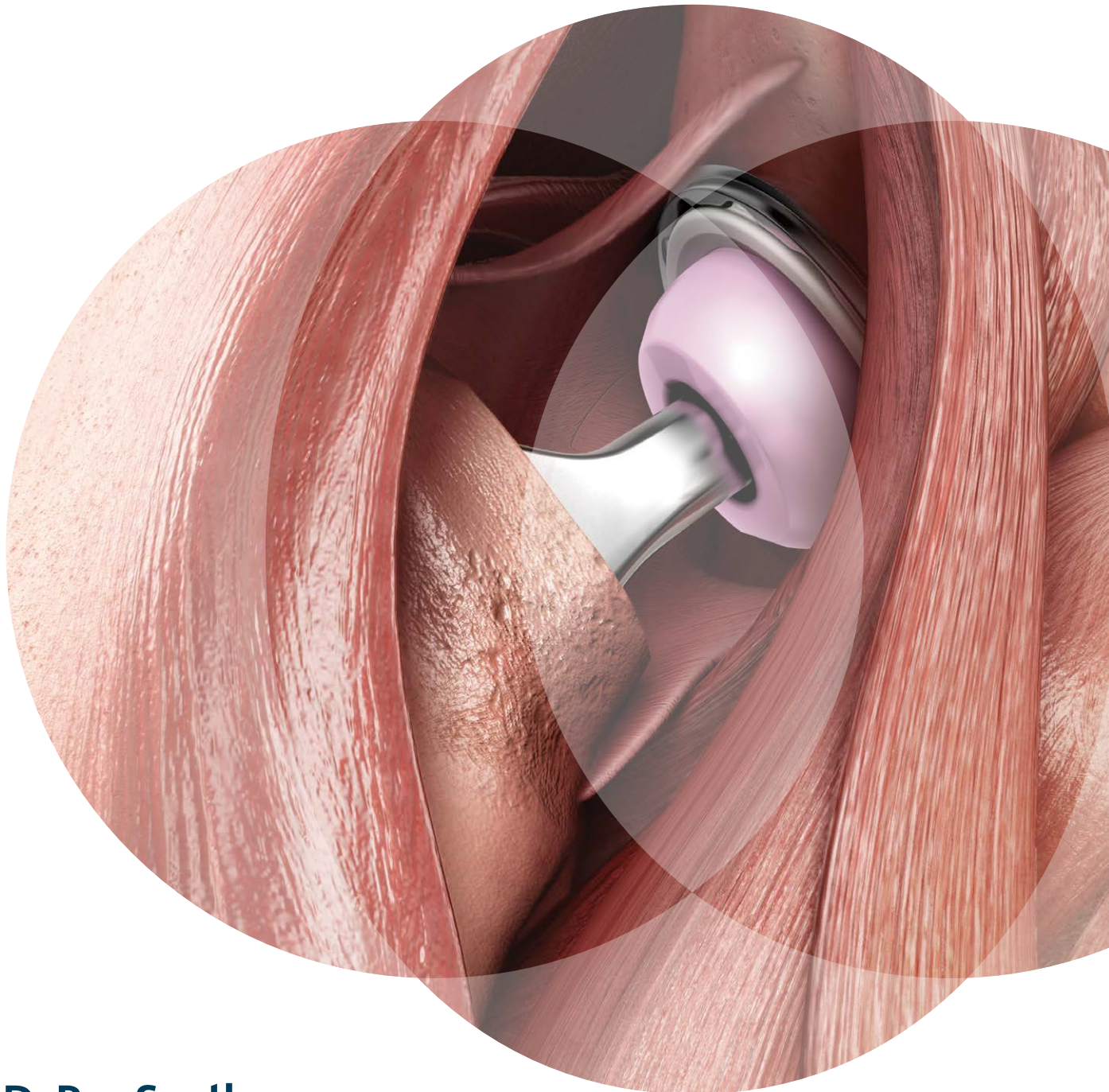


# ANTERIOR ADVANTAGE™

## MATTA METHOD™

Surgical Technique





## VIEW ANTERIOR ADVANTAGE™ MATTA METHOD™ SURGERY FOOTAGE

### On the DePuy Synthes VuMedi Channel

To watch Joel Matta, M.D., perform an Anterior Approach THA surgery using the ANTERIOR ADVANTAGE™ MATTA METHOD™ Solution scan the QR code for immediate access or visit [www.VuMedi.com](http://www.VuMedi.com).



# Table of Contents

---

<b>Introduction</b>	2
<b>Hana® Table</b>	4
<b>Pre-Operative Set-Up</b>	6
<b>Incision and Initial Exposure</b>	12
<b>Exposure</b>	14
<b>Capsular Exposure</b>	16
<b>Dislocation</b>	18
<b>Dislocation and Femoral Head Resection</b>	19
<b>Femoral Head Resection</b>	20
<b>Acetabular Reaming</b>	21
<b>Femoral Preparation</b>	24
<b>Femoral Broaching and Trialing</b>	29
<b>Femoral Trialing</b>	31
<b>Final Implantation</b>	32

## ANTERIOR ADVANTAGE™ MATTA METHOD™ Hip Replacement Philosophy

---

As one of the industry leaders in the Anterior Approach, DePuy Synthes provides the ANTERIOR ADVANTAGE™ MATTA METHOD™ Solution, a differentiated solution for Anterior Approach, inclusive of DePuy Synthes primary and revision hip implant products, instrumentation, enabling technologies, and world class professional education designed to help decrease the learning curve and increase OR efficiency and surgical reproducibility with the goal of better patient outcomes.

This approach is an advanced application of the Smith-Petersen approach using the PROfx®, Hana® or Hana SSXT® tables from Mizuho OSI®. These tables help to streamline the technique, creating a reproducible procedure that minimizes soft-tissue releases through a single incision. The technique does not cut any muscles, but separates them to allow access into the hip joint. The result is that muscles are spared during surgery. With these advantages, the Anterior Approach provides the potential for a quicker recovery compared to traditional hip replacement surgery.

DePuy Synthes has had a long-standing collaboration with Dr. Joel Matta, who has championed and evolved the Anterior Approach in the U.S. and is expanding the adoption outside of the U.S., to what is now known as the ANTERIOR ADVANTAGE MATTA METHOD Hip Replacement.

### **Education Program**

DePuy Synthes continues to work closely with Dr. Matta and surgeon thought leaders around the globe to deliver world class ANTERIOR ADVANTAGE™ Professional Education and Training, products, and enabling technologies to surgeons, patients and hospital teams worldwide. This program features courses offering hands-on cadaveric training, didactic lectures and interactive discussion. Surgical technique papers, surgical technique videos, specially designed ANTERIOR ADVANTAGE Instrumentation, dinner meetings, marketing materials and field specialists further augment DePuy Synthes' comprehensive ANTERIOR ADVANTAGE Professional Education program.

### **Resources**

Additional resources for surgeons, patients and OR Staff can be found at [anterioradvantage.com](http://anterioradvantage.com), [myanterioradvantage.com](http://myanterioradvantage.com), and [jnjinstitute.com](http://jnjinstitute.com).

## About Joel Matta, M.D.

---

Joel Matta, M.D., brought the Anterior Approach to the United States from Europe and has advanced the technique through training and education. The ACTIS™ Total Hip System and the ANTERIOR ADVANTAGE MATTA METHOD Surgical Instruments were designed in conjunction with Dr. Matta and a team of other surgeons. Having performed over 4,000 Anterior Approach hip replacements, Dr. Matta has also been instrumental in the training of many orthopaedic surgeons in the technique, and serves as chairman of DePuy Synthes' ANTERIOR ADVANTAGE MATTA METHOD Professional Education Courses.

Dr. Matta is an orthopaedic surgeon specializing in Hip Disorders related to Preservation, Replacement and Fractures at The Steadman Clinic in Vail, CO, the co-founder and chairman of the Anterior Hip Foundation (AHF, [www.anteriorhipfoundation.com](http://www.anteriorhipfoundation.com)), and the author of over 100 publications and videos on hip replacement and pelvic surgery.

Dr. Matta is a consultant for DePuy Synthes, and receives royalties as the designer of the PROfx®, Hana® and Hana SSXT® tables, which are manufactured by Mizuho OSI.



Joel Matta, M.D.

## Hana<sup>®</sup> Table

---

### **Allows Precise Control of Patient Position, Manipulation and Traction**

Proven performance for Anterior Approach to total hip procedures.<sup>1</sup>  
Allows bilateral hip replacement for qualified patients.

### **Extensive Imaging Capability**

Unrestricted C-Arm access.  
Radiolucent 35 inch (89 cm) cantilevered top section.  
Radiolucent leg spars for uninterrupted imaging.

### **OR Team Engineered**

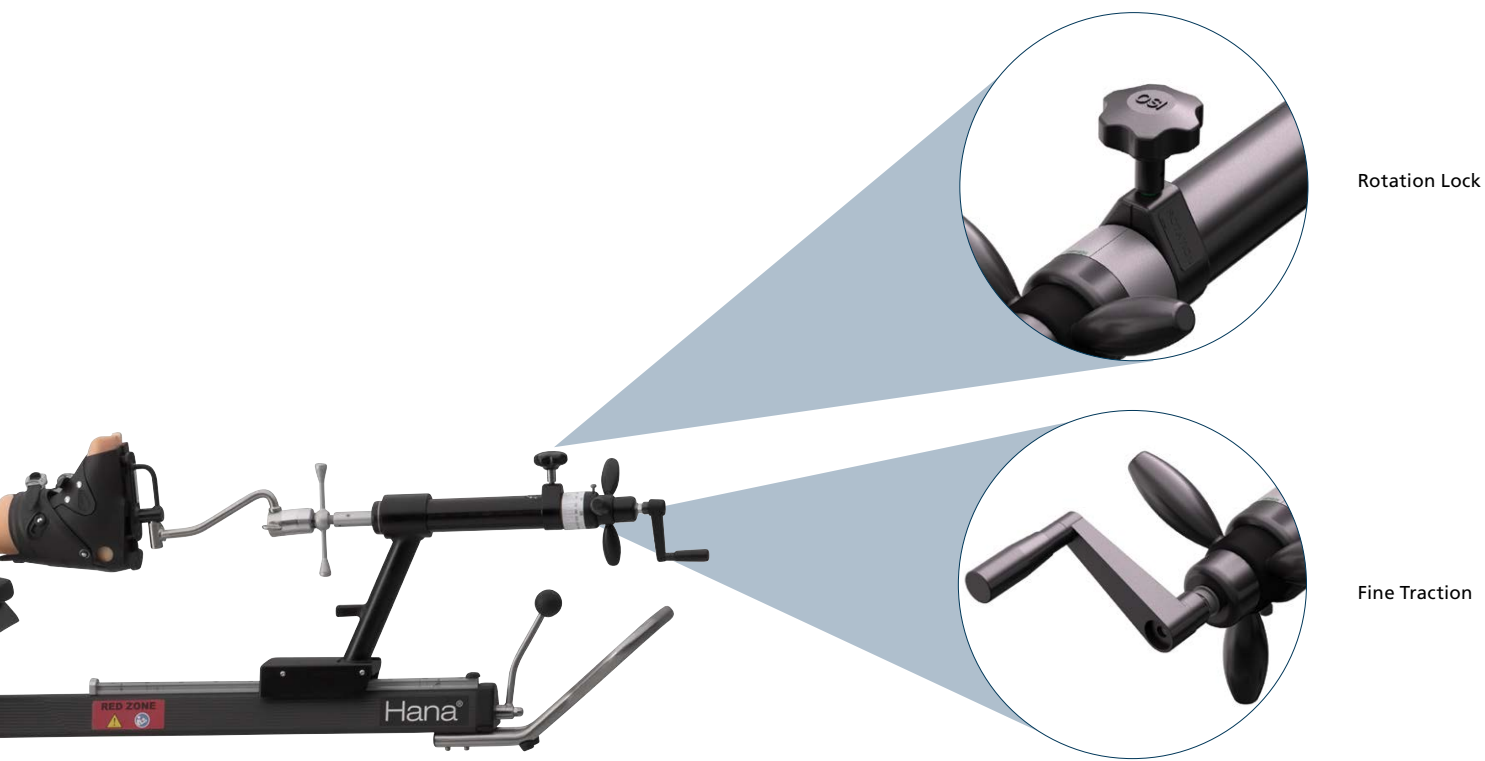
Facilitates OR Team performance.  
Proprietary features designed to make pre-operative and intra-operative protocol easier than a standard OR table.

### **Suited to the Newest Technologies**

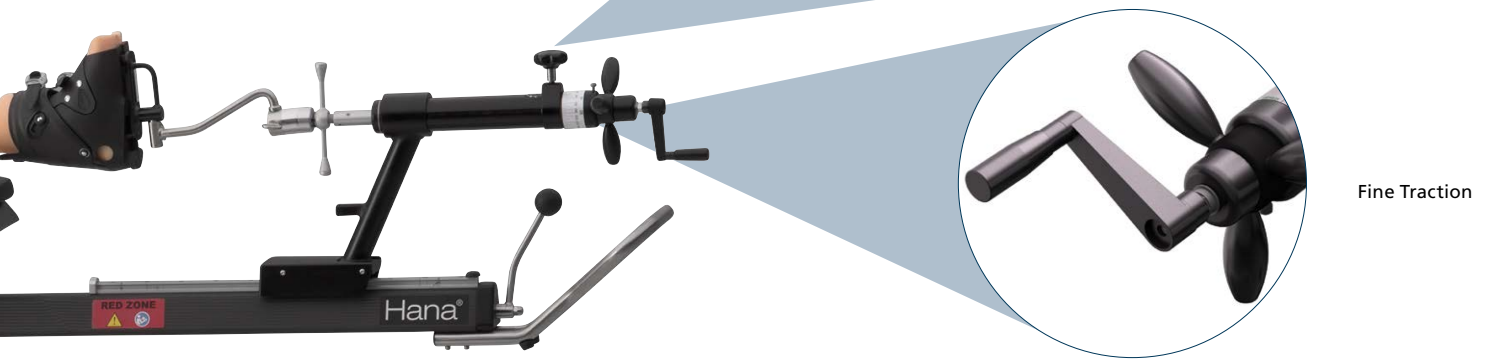
Supports tissue-sparing techniques for MIS procedures.  
Provides new level of surgical assistance for surgeon and OR team.




The Hana<sup>®</sup> table facilitates the surgeon to perform Total Hip Arthroplasty through a single Anterior Approach incision, without detachment of muscle from the pelvis or femur. The table allows hyperextension, abduction, adduction and external rotation of the hip for femoral component placements. Minimizing the disturbance to the lateral and posterior soft tissues may help provide immediate stability of the hip after surgery.




Rotation Lock



Fine Traction



Gross Traction



Internal/  
External Rotation

# Pre-Operative Set-Up

## Patient Set-up and Draping

Before transferring the patient to the Hana® table, it is recommended that the patient's feet be secured into the boots. Apply web roll around the foot, then self-adherent wrap (Coban™) around the upper ankle. With the boot liner out of the shell, position the foot inside, making sure the heel sits all the way into the liner. Each side of the liner will wrap over the top of the foot and ankle. Have someone hold the boot open and slide the foot into the shell, and secure the buckle straps. With a properly sized boot, the toes will be slightly exposed. Test the stability of the boot on the foot by holding the ankle while pulling on the boot handle.

Position the patient on the Hana® table in preparation for surgery. Typically, the patient's arms are placed roughly perpendicular outward and not over the chest. Arms placed on the chest can interfere with femoral preparation later in the procedure.

Ensure that the patient's legs are parallel and in neutral position by lining up the leg spars of the Hana® table (Figure 1). The patient's legs can be raised 3-5 degrees with slight internal rotation. This will work with the diving board of the Hana® table to help reduce lumbar lordosis. Slight gross traction can be added to the non-operative side (patient's left, as shown in Figure 2). This will help stabilize the pelvis around the perineal post, especially when the operative leg is manipulated throughout the procedure. Fine traction should be off when the procedure begins, unless the patient is very tall.

**TIP:** If Hana® table leg spar is in the red zone, use the extension connector to the boot.



Figure 1



Figure 2

## Draping (option 1)

1. Use a clear U drape (non sterile) around the operative area and towards the foot (Figure 3). A towel wrapped over each boot reduces the chance of perforation through the curtain.
2. Place two extra large drapes over the lower extremities starting distal to operative area. Place two large drapes across the top of the patient (Figure 4).
3. Staple three towels around the operative area, one on each side of the incision area and one medial to the incision area (Figure 5).

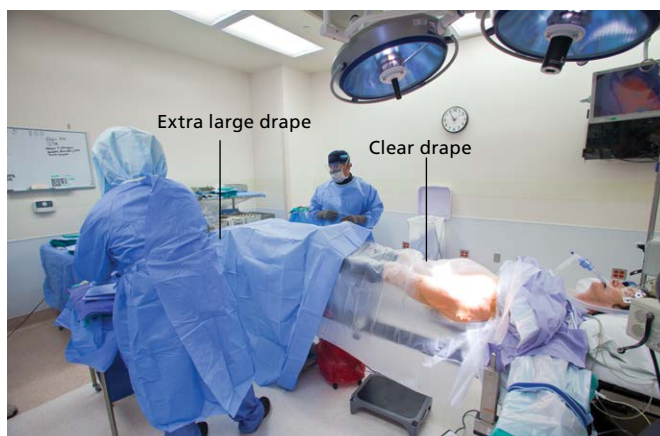

Figure 3

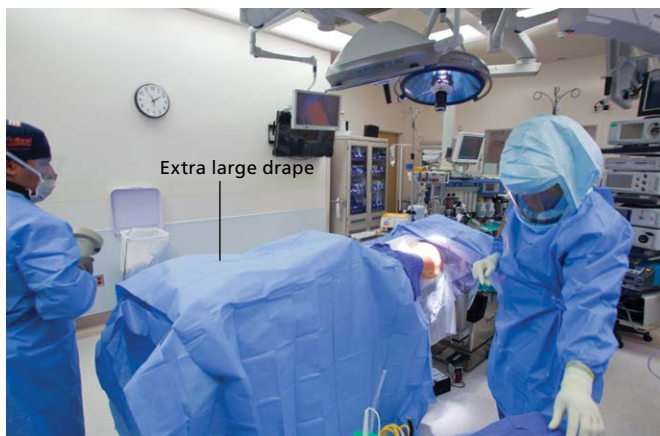

Figure 4

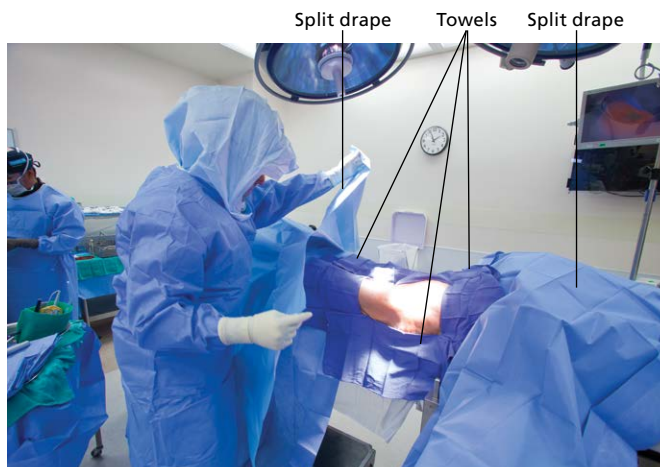

Figure 5

4. Apply an impervious U drape with adhesive around the operative area and extending over the legs. Apply another in the opposite direction over the head.
5. Place a split drape with adhesive proximal and distal to the operative area.
6. Cover exposed skin with iodine incise drape (Figure 6).
7. Cut a small hole in the drape for the femoral hook lift, place the hook bracket on the lift and seal with iodine incise drape (Figure 7).

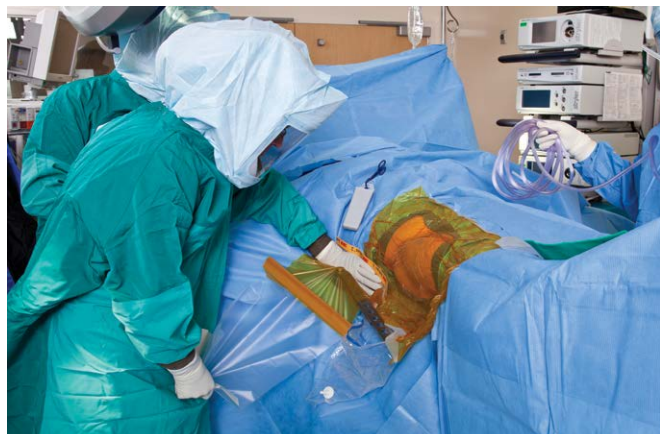

Figure 6

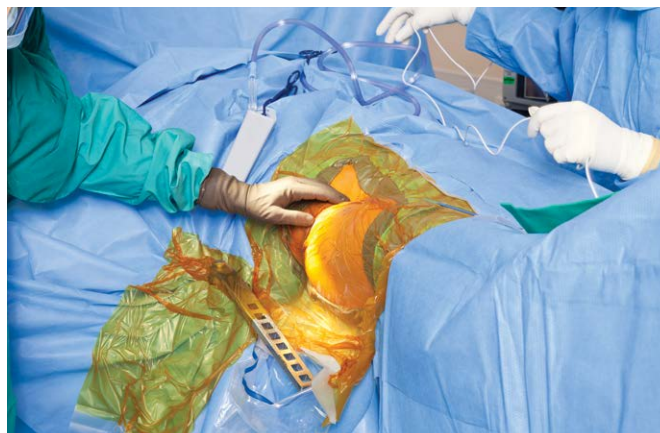
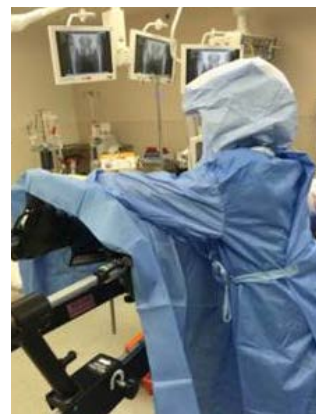
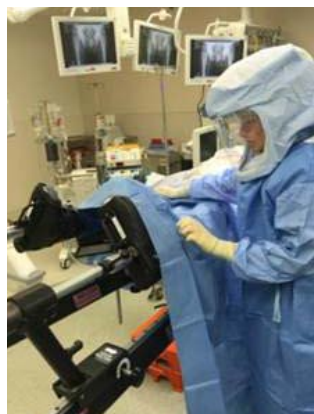Figure 7

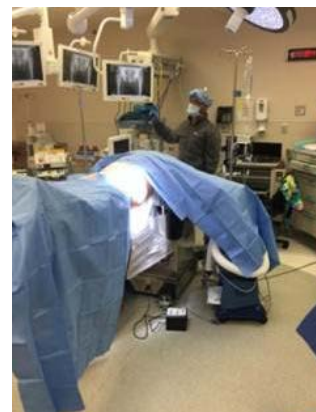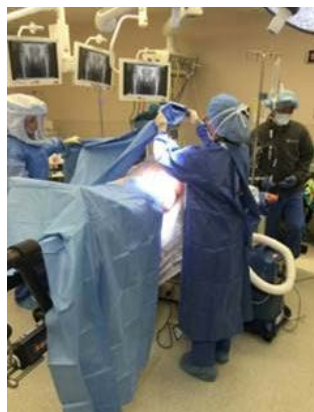---

## Draping (option 2)

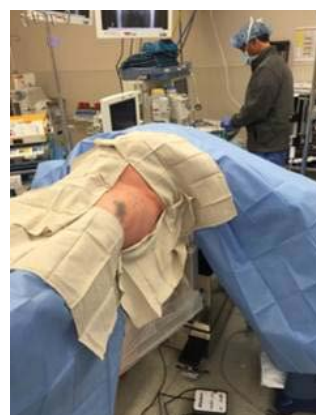
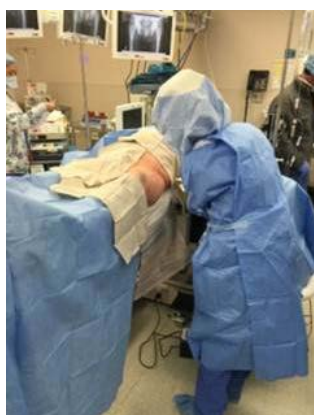1. Apply half the blue drape, preferably with adhesive.



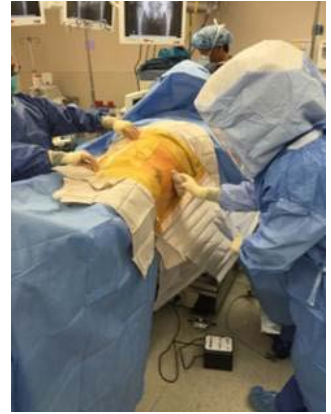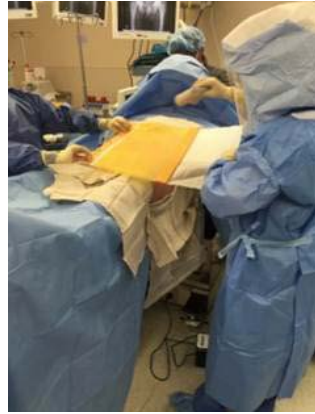
2. Cover the armboards with two quarter sheets.



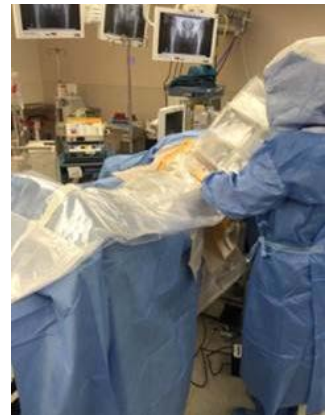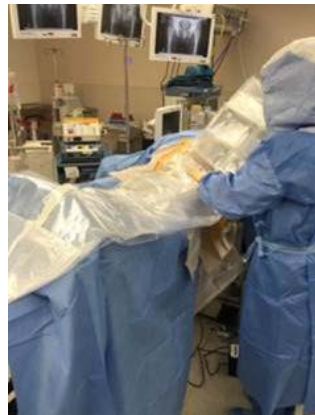3. Apply sterile hand towels with a stapler.



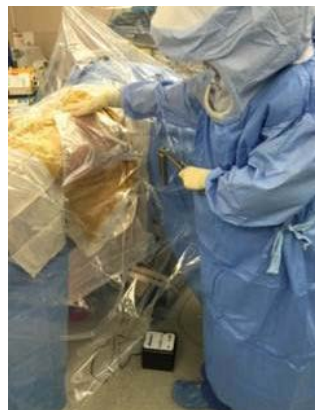- 
4. Cut one long ioban drape so that two-thirds can be applied over the incision site.



5. Cover the patient with a shower curtain drape.



6. Take the remaining one-third ioban drape and cover the base of the table hook. Place the table hook over the drape.



# Room Set-up (left hip)

The OR is set up such that the instruments are on the operative side of the patient. Generally, the use of 2 back tables (A), 1 Mayo stand (B) and 1 basin stand (C) is sufficient, creating an L-shaped area. The C-Arm (D) is positioned on the non-operative side, perpendicular to the patient (Figure 8).

A typical OR team will consist of the surgeon, physician's assistant, anesthesiologist, scrub nurse, circulating nurse/table operator and X-ray technician.




Figure 8

# Incision and Initial Exposure

Mark the locations of the iliac crest, greater trochanter and the anterior superior iliac spine (ASIS) (Figure 9). Start the incision approximately 3 cm lateral and 1 cm distal to the ASIS, and continue in a posterior and distal direction toward the anterior border of the femur. The incision will be 8-10 cm and parallel to the fibers of the tensor fascia lata muscle.

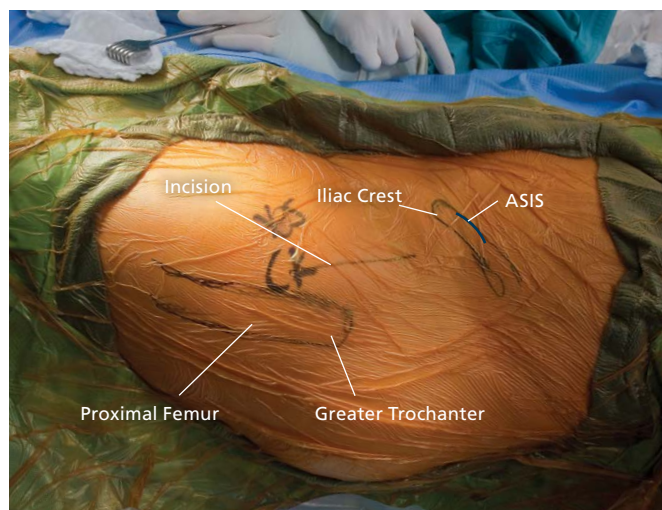


Figure 9

The tensor fibers are visible through the translucent fascia (Figure 10).

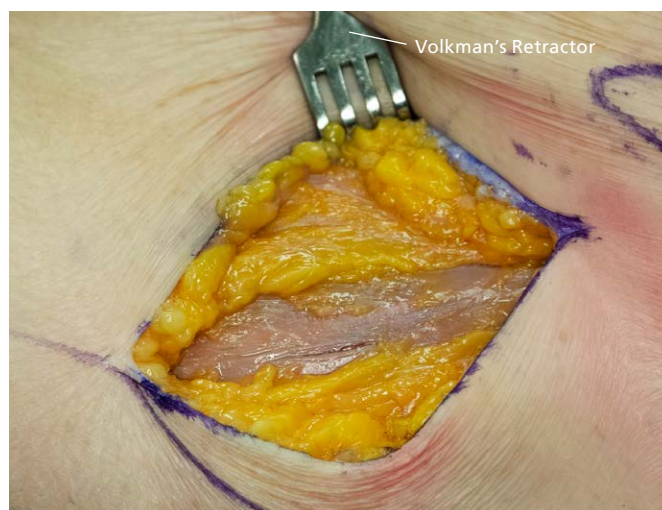

Figure 10

Incise the fascia over the tensor and parallel to its fibers. Extend the fascial split beneath the skin proximal (toward the ASIS) and distal (Figure 11).

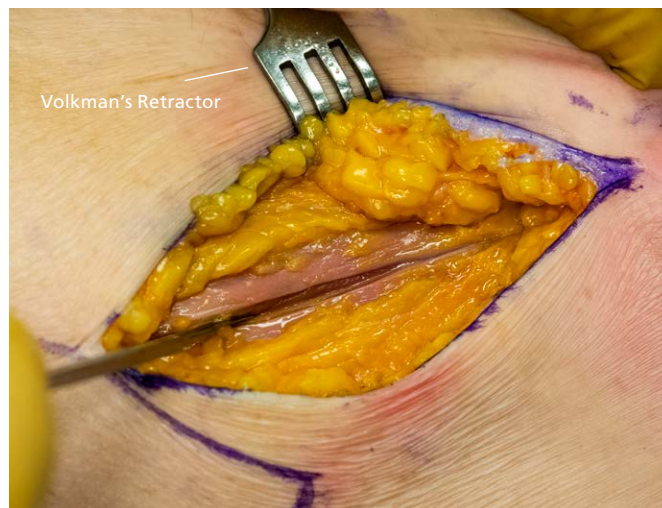

Figure 11

Coagulate the vessel that perforates the fascia.

The fascial incision is typically between the anterior two-thirds and posterior one-third of the tensor muscle (Figure 12). Avoid splitting the iliotibial band, which lies along the posterior border of the tensor. Splitting this will lead to the muscle interval posterior to the tensor commonly known as the Watson-Jones approach.

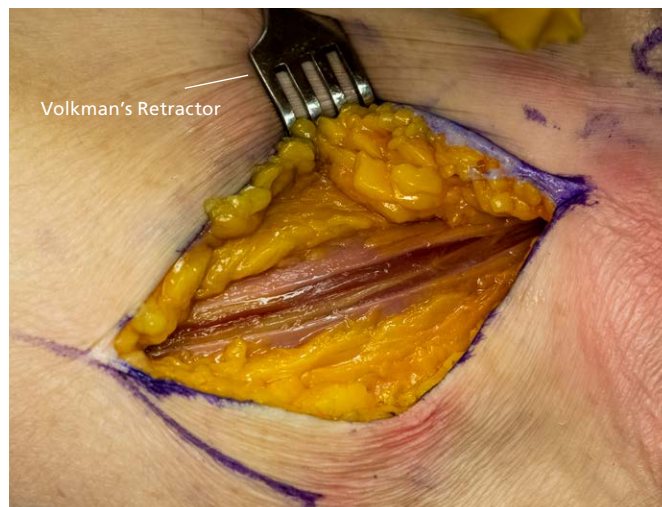

Figure 12

# Exposure

Lift the anterior tensor flap with an Allis Clamp and using your finger, bluntly dissect inside the tensor sheath, anterior and medial to the tensor muscle.

The location and obliquity of the incision, along with the deep dissection within the tensor sheath, protect the lateral femoral cutaneous nerve.

Palpate the anterior inferior iliac spine (AIIS) and move your finger distal and lateral to palpate the anterior hip capsule. Place a blunt-tipped Narrow Cobra Retractor (259807001) lateral to the hip capsule and locate the origin of the rectus femorus. Retract the tensor and gluteus minimus laterally. Use the Hibbs Retractor and retract the sartorius and rectus femorus medially (Figure 13).

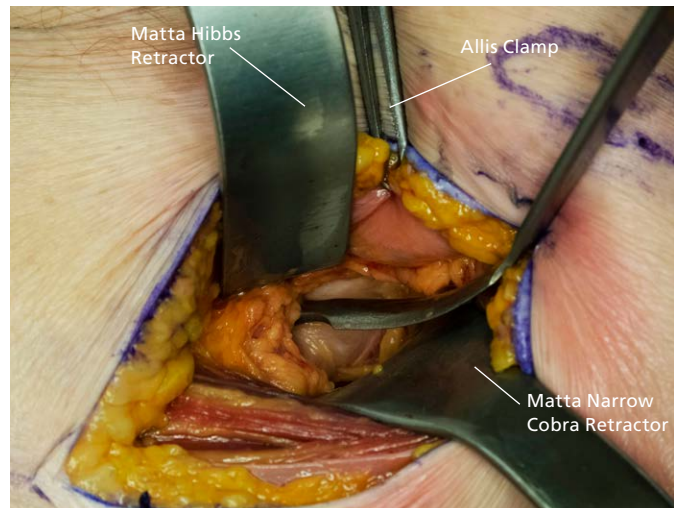


Figure 13

## Alternative Option

To elevate the iliopsoas and rectus femorus muscles from the anterior capsule, pass a Key/Cobb elevator posterior to the origin of the rectus femorus and anterior to the hip capsule, directing it medial and distal (Figure 14).

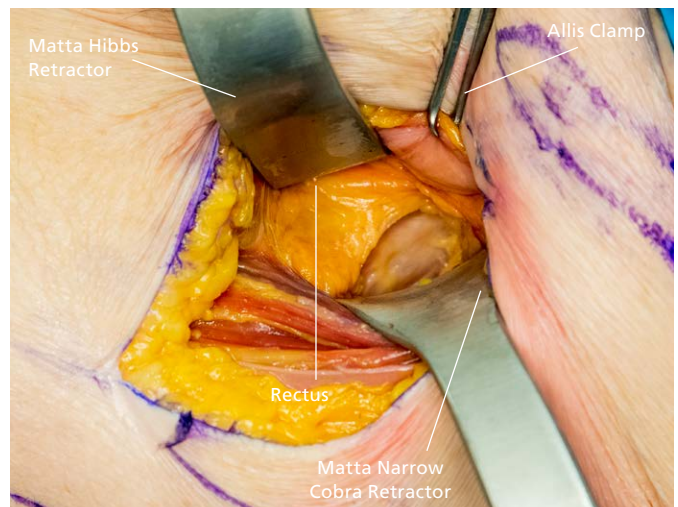


Figure 14

Place the tip of the Short Curved Hohmann (259807003) on the antero-medial hip capsule to retract the rectus femorus and sartorius medially. As the Short Curved Hohmann and Narrow Cobra Retractor retract medially and laterally, use your finger to tease the fascia lata off the distal tensor to enhance exposure and avoid rupture of the tensor fibers.

Retract the tensor laterally with a Hibbs Retractor to facilitate visualization of the anterior capsule. Dissect distally to enhance exposure. The lateral femoral circumflex vessels are also now visualized distal to the hip capsule. Cut and tie, or cauterize both sides of the vessel, taking care to cauterize all of the branches (Figures 15 and 16).

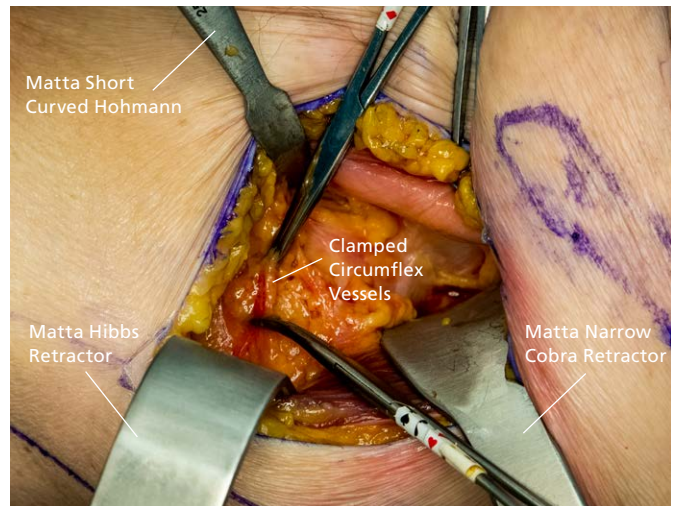


Figure 15

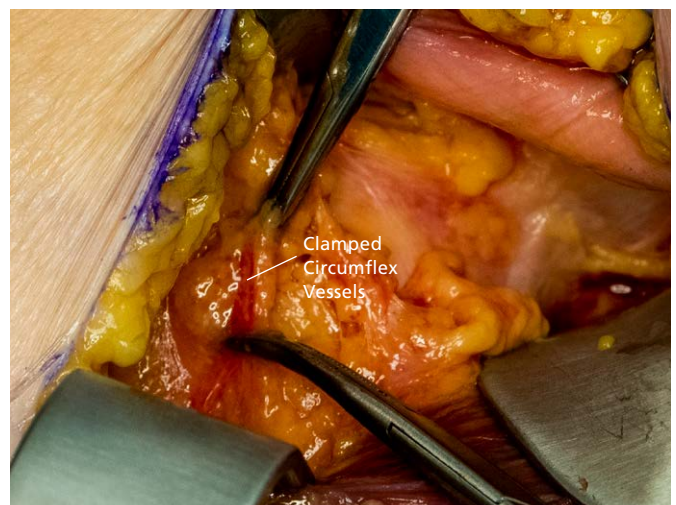

Figure 16

# Capsular Exposure

For more mobility of tensor muscle, release the fascia layer distal to the cauterized vessels. Retract the tensor to visualize the fibers of the vastus lateralis muscle.

Cut the capsule parallel to the neck at the junction of the anterior and lateral/superior capsule; continue down to the base of the neck, until reaching the tubercle at the lateral extent of the intertrochanteric line.

Ensure that the lateral shoulder (saddle) of the neck is visible where the lateral portion of the neck joins the tip of the greater trochanter (Figure 17).

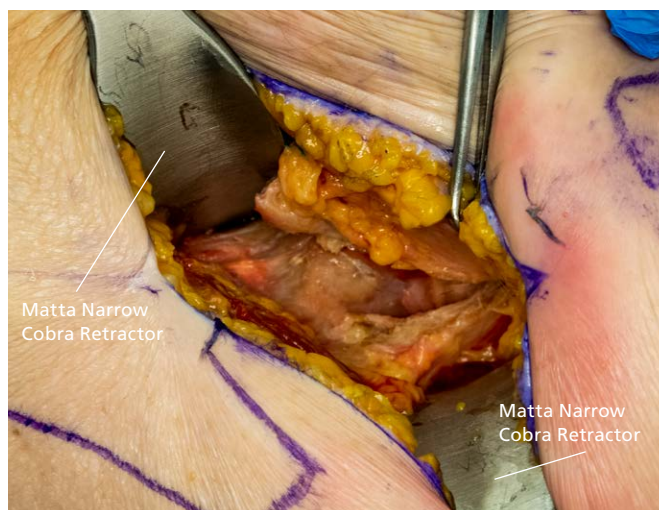

Figure 17

From the distal extent of the capsular incision, detach the capsule from the intertrochanteric line in a distal and medial direction (junction of the anterior capsule and the origin of the vastus lateralis muscle) (Figure 18).

Cut the anterior capsule off the base of the neck. This ensures visualization and mobility of the femur during femoral preparation. Tag the anterior capsule with a suture along the longitudinal cut edge. Place the Narrow Cobra Retractor (259807001) under the anterior capsule and around the medial neck. Detach the lateral capsule from the inter-trochanteric line area.

Watch for and cauterize bleeders along the intertrochanteric line. Place a tag suture on the cut edge of the lateral capsule, near the greater trochanter. Place the Narrow Cobra Retractor inside the lateral capsule along the lateral neck. Slide the tip of the Short Curved Hohmann (259807003) under the anterior capsule and over the anterior rim.

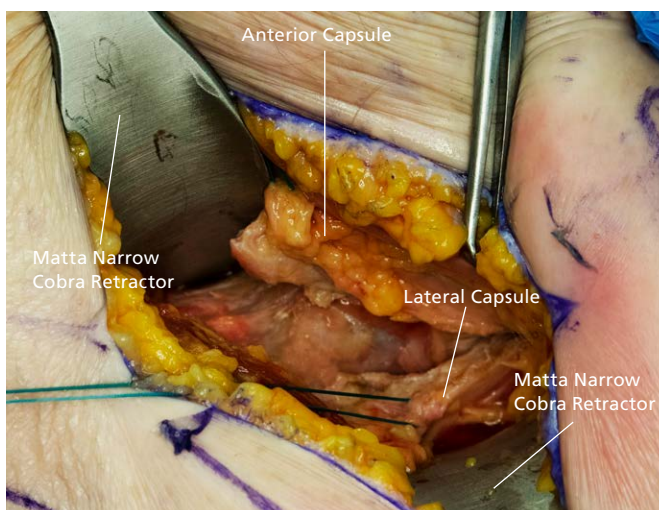


Figure 18

Locate and remove the labrum to visualize the bony rim of the acetabulum. The labrum is often ossified (acetabular osteophyte). If so, excise with an osteotome, as failing to do so may make inserting the Bone Skid difficult. Request gross traction be applied and lock. Use approximately 3-4 turns of fine traction to pull the femoral head away from the acetabulum (Figure 19).

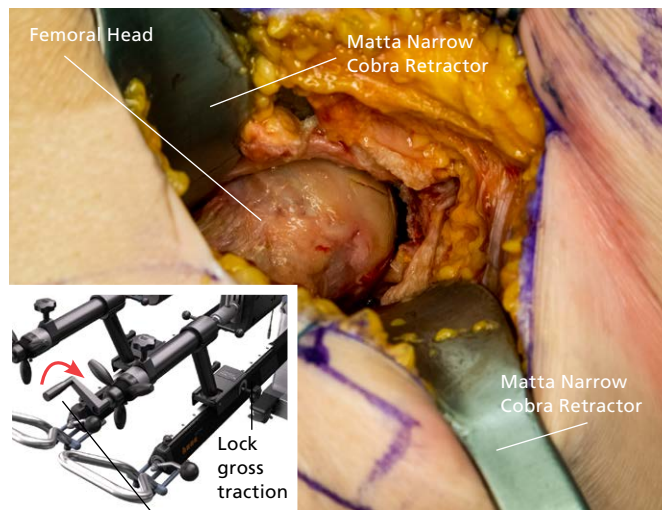


Figure 19 3 or 4 turns of fine traction

Push the Hip Skid (259807002) between the superior head and acetabular roof and “lever” to loosen the soft tissues. The T-handle Hip Skid can also move medial around the head to cut the ligament teres.

Request the operator to remove 1-2 turns of fine traction. Unlock the rotation knob from the table and place the Hip Skid between the femoral head and anterior-superior rim (Figure 20). Mobilize the head with the skid and externally rotate the hip.

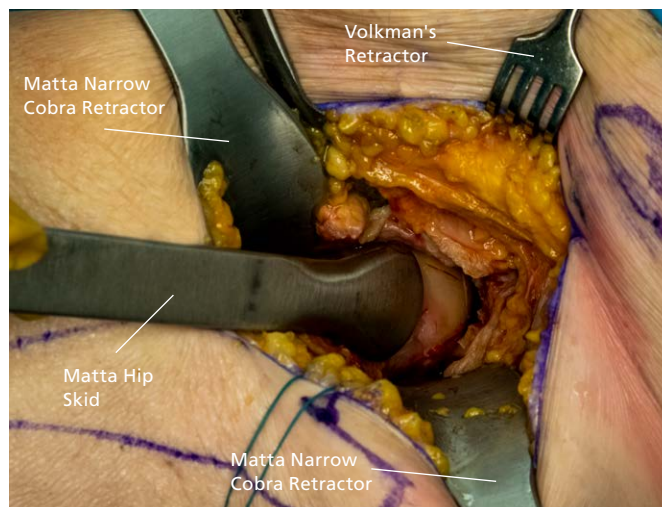


Figure 20

# Dislocation

Under power, insert the Femoral Head Short Corkscrew (259807010), or Femoral Head Long Corkscrew (259807011), into the femoral head in an anterior to posterior direction and attach the Silicone T-Handle Hudson (259807012) (Figure 21).

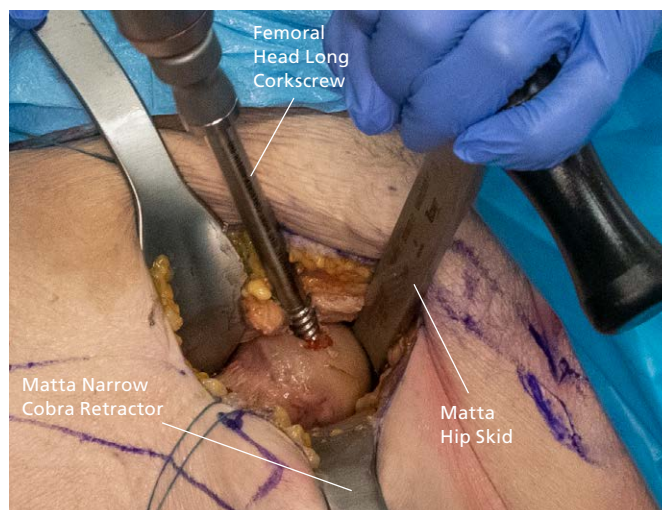


Figure 21

Pull upward on the T-handle attached to the Femoral Head Corkscrew while levering with the Hip Skid (259807002) to dislocate the head anterior and lateral (Figure 22).

Maximally externally rotate the extremity and lock the rotation control. The surgeon can aid in rotation by pushing the handle of the Femoral Head Corkscrew towards the floor.

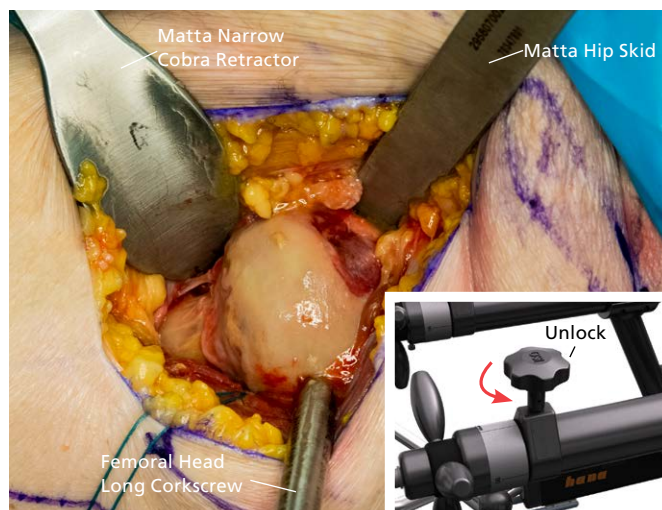


Figure 22

# Dislocation and Femoral Head Resection

Remove the Hip Skid (259807002) and readjust the Narrow Cobra Retractor (259807001) medial and lateral to the neck. Using a Short Curved Hohmann (259807003) to slide under the muscle, with the tip around the lesser trochanter, retract the vastus origin. Release the capsule off the medial and posterior-medial neck (Figure 23). This release will expose the lesser trochanter and will later enhance femoral mobility and access. The femur at this point is externally rotated 90 degrees and lateralized.

Identify and coagulate bleeders near the base of the neck. Unlock the table rotation and internally rotate the leg to reduce the hip.

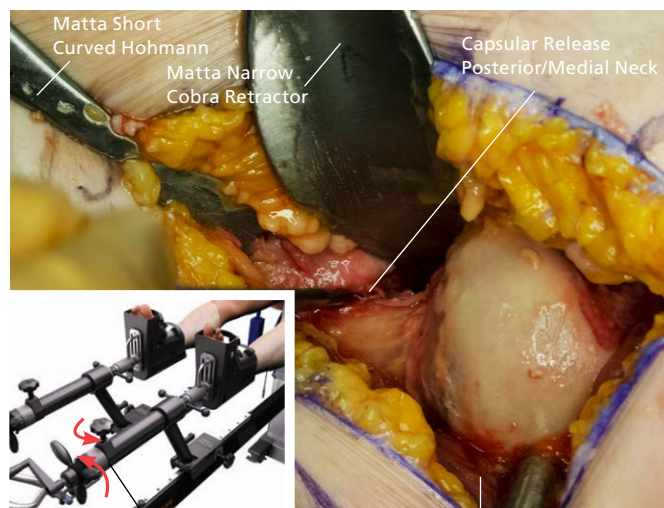


Figure 23 Unlock rotation and internally rotate

The neck cut should be based on the pre-operative templating. Most often, the lateral portion of the neck cut comes near the lateral shoulder of the neck, by the junction of the greater trochanter. This landmark can be used as an indicator for the neck cut.

Using the Hibbs Retractor (259807000) to protect the tensor from the Oscillating Saw Blade, aim in a posterior-medial direction so the excursion of the saw does not come into contact with the posterior greater trochanter. Make the cut using the saw. Use an Osteotome with the blade parallel to the long axis of the body to finish the cut (between the greater trochanter and the base of the neck) (Figure 24). This will protect against cutting the trochanter.

**Note:** An in-situ neck cut may also be performed, if preferred. A neck cut following dislocation is described here since dislocation aids with femoral mobility and exposure.

**Note:** There is a tendency to make the neck cut too vertical, so make it more perpendicular to the shaft.

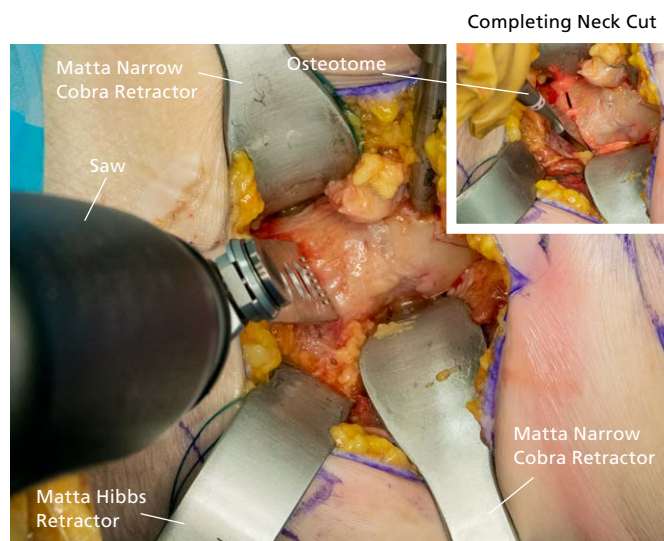


Figure 24

# Femoral Head Resection

While removing the head-neck segment prevent sharp bone edges from catching on muscles by rotating the head to bring the head out first (Figure 25).

Externally rotate the hip about 45-60 degrees. Pull up on the tag suture attached to the anterior capsule and place a Short Curved Hohmann Retractor (259807003) under the capsule and over the inferior part of the anterior rim. Place the Narrow Cobra Retractor (259807001) over the mid-portion of the posterior rim with the tip outside of the labrum, but inside of the capsule.

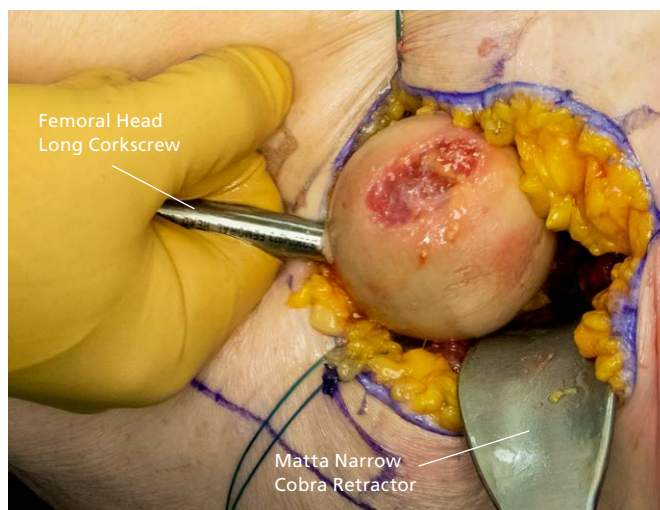


Figure 25

Cut the inferior capsule transversely to enhance distal acetabular exposure. With a knife, excise residual posterior, and if present, anterior labrum (Figure 26).

**Note:** Using the Capsular Retractor (259807008) place one point near the rim of the acetabulum on the posterior lateral capsule and the other point on the anterior capsule. Then spread them open to expose the acetabulum.

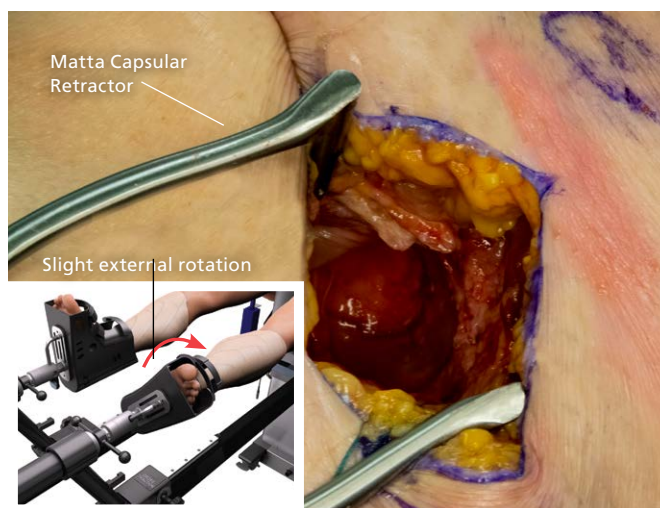


Figure 26

# Acetabular Reaming

The goal of acetabular reaming is to create a spherical cavity that will provide an intimate press and frictional stability with the porous surface Pinnacle cup. The other purpose is to establish the correct center of rotation that is as close as possible to the hip's pre-disease center of rotation. It is preferable during reaming to apply strong pressure along the reamer shaft. The initial reaming, with a smaller than final reamer will be done with continuous rotation of the reamer and minor changes of the shaft direction to facilitate reamer advancement and this reamer will for the most part establish the cup center. Subsequent reaming to establish the final circumference is also best done with strong pressure, however this reaming is typically best done with intermittent "pulses" on the reamer trigger. As the final size is reached there should be palpable torque and reaming should be stopped when there is a slight decrease in sensed torque (bite) magnitude. A common mistake is to keep the final size reamer rotating continuously while making directional changes.

Begin reaming the acetabulum by aiming the reamer anterior to by 25 degrees to the coronal plane, and proximal by 25 degrees to the transverse plane. It is not needed to ream in the direction of correct final inclination and anteversion. In fact it is an error to do this because aiming the reamer in the direction of final cup insertion will typically take away too much superior bone and the cup will end in a too proximal position. Check progress by visualizing the acetabulum and by checking with the C-Arm. Look for and control bleeding near the obturator foramen.

Before reaming to the final templated size, it is recommended that the reamer position be checked with fluoroscopy. Rotate the C-Arm image (A/P view) on the screen until the pelvis image appears level (when the transverse anatomic line is horizontal). With the image centered over the midline, the coccyx should be pointing right at the symphysis, and the obturator foramina should look identical. This may require the C-Arm to orbit and rainbow.

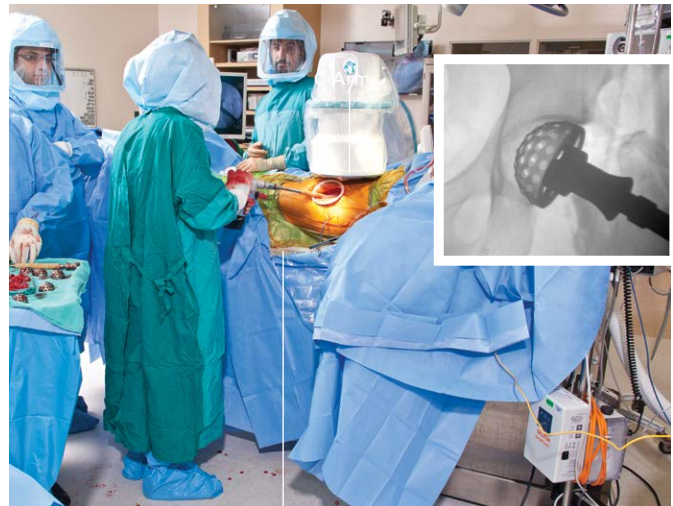

Figure 27

After leveling the image and pelvis, center the image over the operative acetabulum. The image of the reamer shows where the cup will be centered (Figure 28). The cup should have a good circumferential fit.

At the completion of reaming there is typically incomplete reaming of the rim of the acetabulum and cartilage may remain along the rim. The C-arm will show satisfactory medialization and fit however may also show and incomplete reaming of the lateral roof and what appears as a gap between the reamer/cup and lateral roof.

Reaming does not have to be progressive until the rim has been reamed; if this is done the cup will typically be too large. It is the author's preference to ream "line to line" where the final reamer size corresponds numerically to the chosen cup size though 1 mm undersize is also an option and bone quality may be a deciding factor.

**Tip: A cup that is too large may lack purchase and an overhanging anterior edge may impinge on the iliopsoas tendon.**

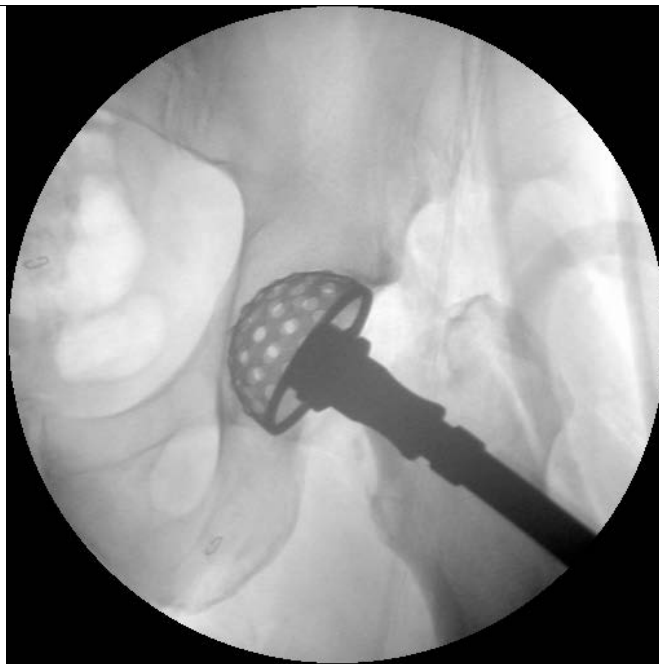

Figure 28

When the appropriate size has been reamed, insert the PINNACLE® Trial or Cup (trial liner optional). After confirming alignment and position, remove the trial (if used) and insert the final prosthesis. Final insertion and seating of the PINNACLE Cup is ideally performed with the KINCISE™ Surgical Automated System.

**See the KINCISE System Surgical Brochure found at [KINCISEsystem.com](http://KINCISEsystem.com) for ordering information.**

For surgeons unaccustomed to the supine position, it is common to place the cup with too much inclination and anteversion. The correct insertion orientation is typically with the insertion device more parallel to the floor and long axis of the body than expected. Check for proper placement of the final component with the C-Arm. Aim for a targeted 40-45 degrees of inclination and 20-25 degrees of anteversion (Figure 29). The PINNACLE Cup inclination and anteversion is ideally guided and confirmed with VELYS™ Hip Navigation. The angle and proportions of the image of the ellipse of the rim of the Cup indicates inclination and anteversion.

**Refer to [VELYSDigitalSurgery.com](http://VELYSDigitalSurgery.com) for VELYS™ Hip Navigation information.**

**Note: These angles are the preferred method by the surgeon author. Target placement often varies based on surgeon preference and approach.**

Place the final component into position and impact the cup. Before inserting the liner, check the Acetabular Retractors. The Narrow Cobra Retractor (259807001) should be placed over the mid-portion of the posterior rim. Insert the liner into the cup, seating it into the cup (Figure 30). Impact the liner and perform a final check of the cup and liner placement under X-ray. The author prefers that if no screw hole PINNACLE Cups or Pinnacle 100 (no holes) is used, then add the hole eliminator. If the inserted cup does not have purchase with the reamed cavity, select a reamer that is 1mm smaller than the cup and ream slightly deeper (1 or 2mm). Re-insert and re-impact the cup.

Final seating of the PINNACLE Liner is ideally performed with the KINCISE Surgical Automated System. The PINNACLE liner Inserter Tip should be utilized with the KINCISE Cup Impactor for Liner impaction.

**See the KINCISE System Surgical Brochure found at [KINCISEsystem.com](http://KINCISEsystem.com) for ordering information.**

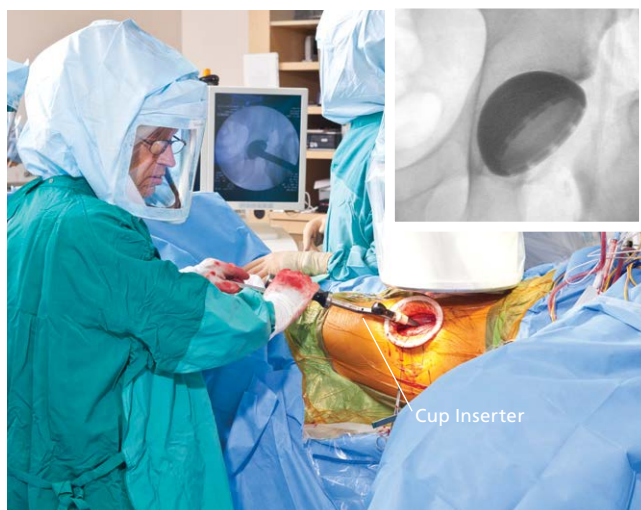


Figure 29

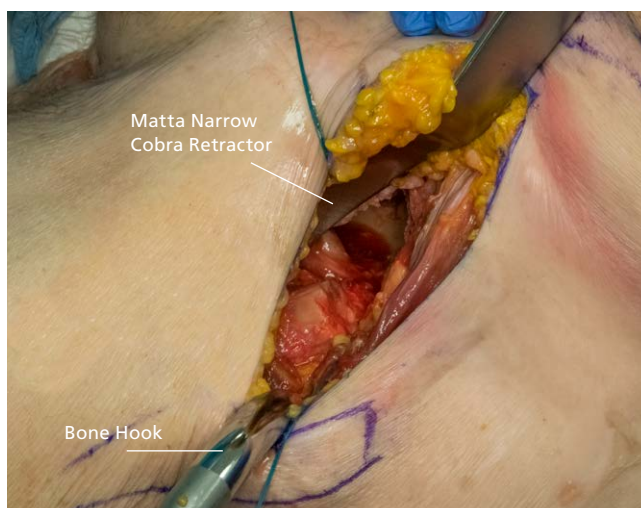


Figure 30

# Femoral Preparation

Unlock the gross traction and internally rotate the femur to the neutral position. Palpate the vastus tubercle, and place the tip of the Bone Hook (either the right or left, corresponding to the operative hip) just distal to the vastus tubercle and around the posterior femur (Figures 31–32).

It is best that the surgeon control the extremity/femur external rotation by supporting the knee with one hand and grasping the foot boot (covered by drapes with the other). The surgeon then applies extremity torque that he or she is comfortable with (depending on patient size and bone quality) and the unscrubbed table operator locks the position. In many cases, initial femoral external rotation is short of 90 degrees, but subsequent soft tissue releases will allow 90 degrees of femoral external rotation.

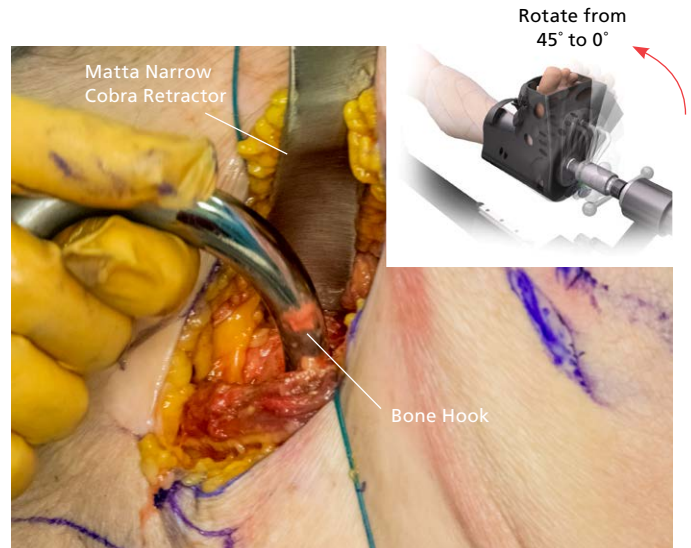


Figure 31

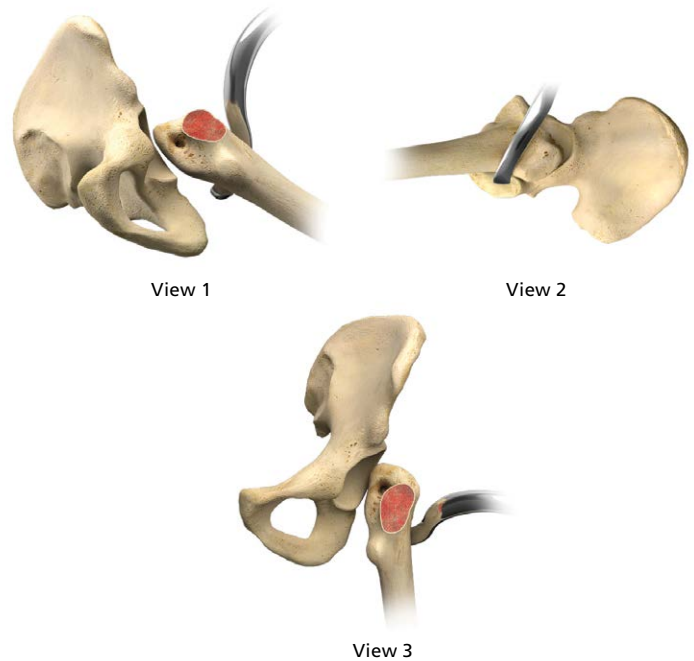


Figure 32

Externally rotate the foot approximately 110-120 degrees. This will result with the femur rotating approximately 90 degrees. Place the Posterior Retractor (259807005 (RT), 259807004 (LT)) (Figure 33a and Figure 33b) around the posterior cortex of the femur, then extend and adduct the leg (Figure 33c). Some surgeons have observed the posterior greater trochanter to “catch” behind the posterior acetabular rim. This potential problem however is obviated if the hip is dislocated prior to the neck cut and lateral mobility of the femur thereby obtained.

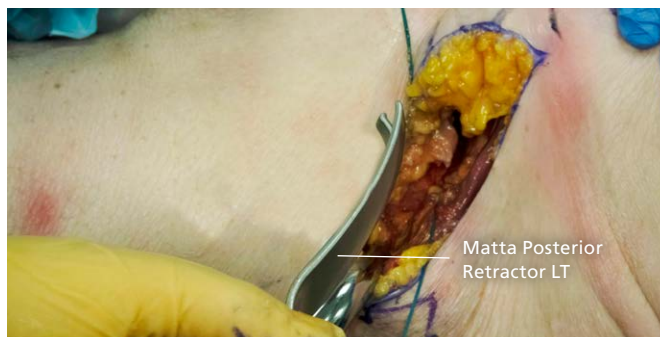

Figure 33a

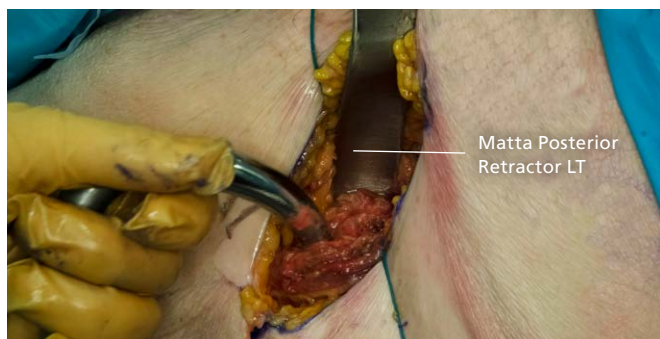


Figure 33b

**Foot EXTERNALLY rotated 110-120 degrees  
(Rotation of femur 90 degrees)**

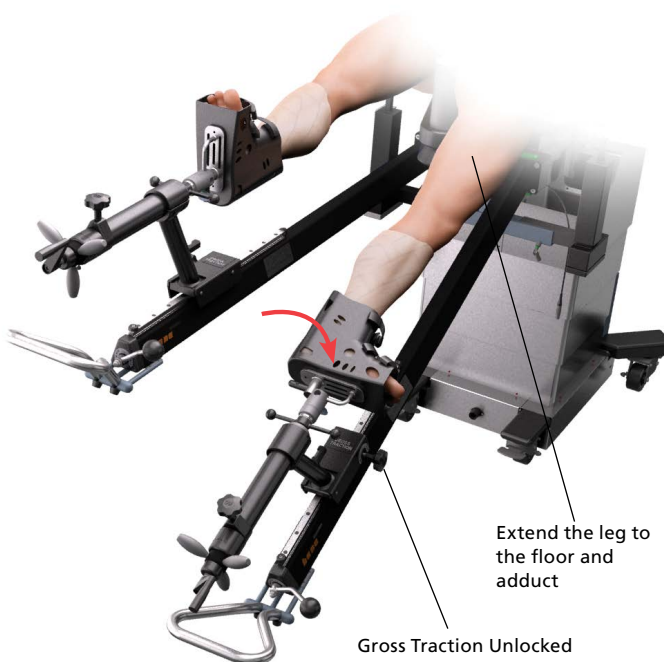

Figure 33c

Place the Bone Hook into the bracket on the table and manually lift the Hook. Lift the femur and raise the jack to bring the bracket up to hold the Hook.

Next, place the Greater Trochanter Retractor (259807006) over the tip of the greater trochanter, outside the hip capsule (Figure 34).

**Note:** Use the table bracket as a shelf, not as a lift for the Bone Hook and femur.

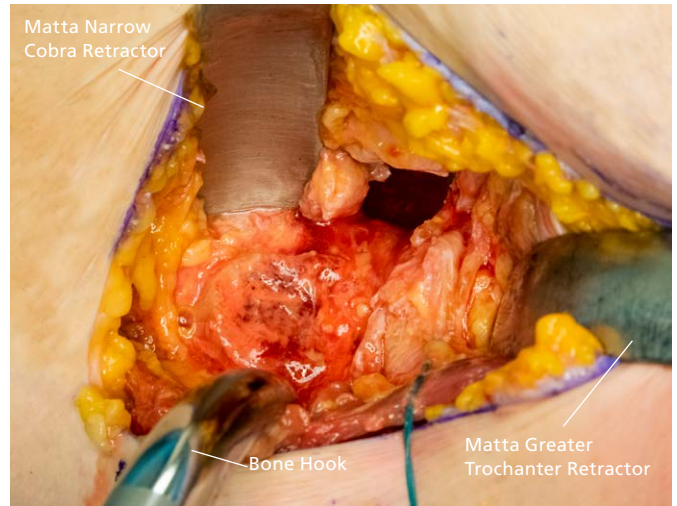


Figure 34

Using the tag stitch on the lateral capsule, pull up on the tag, and cut between the lateral capsule and minimus down to the medial trochanter. There may be spikes of the lateral neck remnant that needs to be removed by a rongeur (Figure 35).

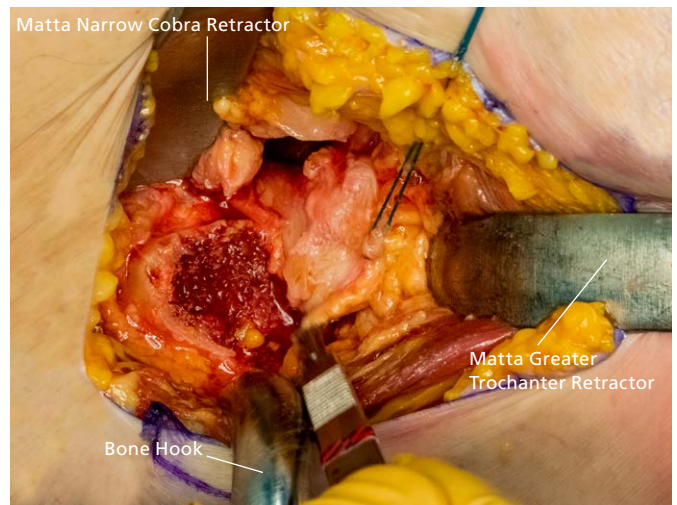


Figure 35

Cauterize the region of the retinacular vessels along the posterior superior neck. The piriformis and obturator internus tendons insert on the anterior portion of the greater trochanter. Typically, the piriformis tendon lies superior to the anterior greater trochanter. The obturator internus tendon typically lies medial to the tip of the greater trochanter. Further release of the capsule from the medial trochanter can enhance femoral mobility.

The tendons of the obturator internus, piriformis, and obturator externus can now be identified. (Figure 36).

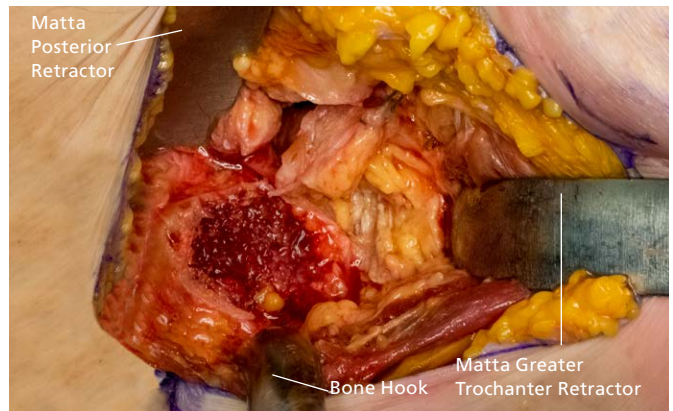


Figure 36

A manual lateral and anterior pull on the Bone Hook (after soft tissue release) can give further femoral exposure. This position is maintained by raising the hook bracket. At this point, further femoral rotation, if necessary, may be possible by releasing hook tension, flexing the hip to neutral, externally rotating further then again extending the hip to the preparation position.

Use the Long-Handled Rongeur to remove the lateral neck remnant and, if necessary, to get more lateral into the inside of the greater trochanter (Figure 37a). Once released and ready for broaching, take out the Hohman retractor and replace with the Matta Greater Trochanter Retractor (259807006).

**Tip:** After removing the lateral neck remnant, if your exposure is not adequate to begin broaching, check the hook tension manually and then if necessary, sharply expose the medial cortex of the greater trochanter. On a right hip this would be called the 1 o'clock release or the 11 o'clock release on a left hip (Figure 37c). This release includes transection of the obturator internus tendon (Figure 37b)

If more release is needed then move closer to the tip and release the piriformis tendon. Lift on the hook and the femur should be more mobile. Pull on the hook, lateral and anterior and you should see the femur come more anterior.

The strong insertion of the obturator externus tendon is seen in the piriformis fossa and should be preserved. The obturator externus pulls the femur in a medial direction and thereby has an important anti-dislocation function.

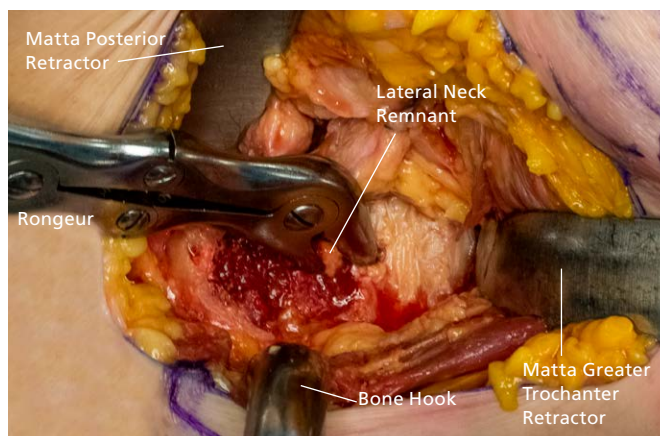


Figure 37a

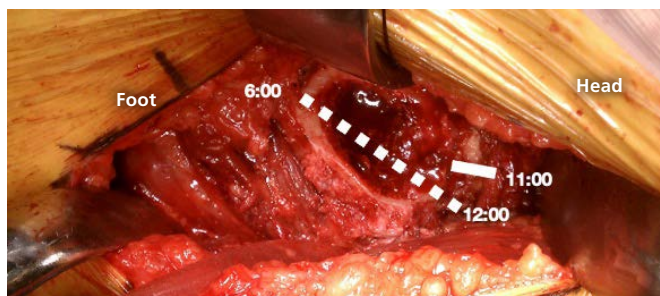


Figure 37b

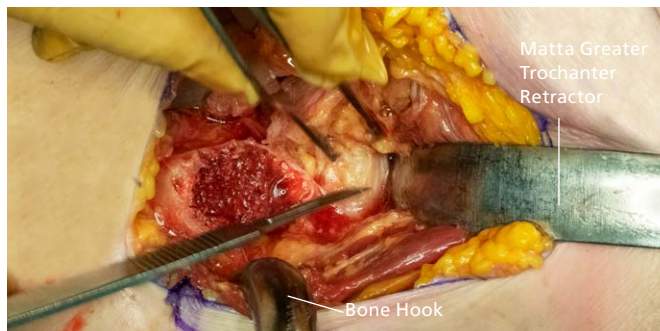

Figure 37c

# Femoral Broaching and Trialing

## Broaching

Start the broach insertion near the calcar utilizing the Starter Broach (Figure 38a).

Orient the broach such that the plane of the broach is parallel to the posterior cortex. Sequentially broach to the proper size with the broach attached to the selected broach handle. Femoral broaching is ideally performed with the KINCISE Surgical Automated System (Figure 38b).

**See the KINCISE System Surgical Brochure found at [KINCISEsystem.com](http://KINCISEsystem.com) for Ordering information.**

Broaching either manually or with the KINCISE System will progressively enlarge the metaphyseal cavity by compacting and shaping the cancellous bone. Stability of the final broach is enhanced if the initial small broaches are placed in varus with the tip starting near the calcar and proceeding distal and somewhat toward the inner lateral metaphyseal cortex. As the broaches increase in size the varus orientation will spontaneously correct. Check the depth of broach insertion in relation to the tip of the greater trochanter and match this to the templated pre-operative plan.

Broaching should continue until rotational stability is achieved. If using the ACTIS Stem, the final Broach/Stem seen on the AP flouro view will typically not fill the proximal femur canal. The distal portion of the broach/stem should appear to contact the inner lateral cortex with a radiolucency present between the distal broach/stem and medial cortex. When the final and desirable broach size is reached, rotational stability will be present (moderate torque) and the broach will only advance less than one millimeter with each KINCISE Surgical Automated System pulse.

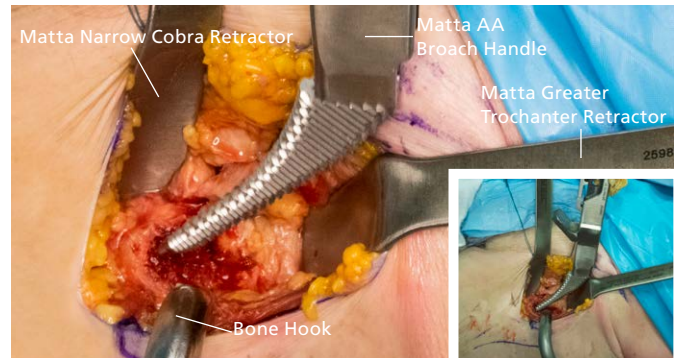


Figure 38a

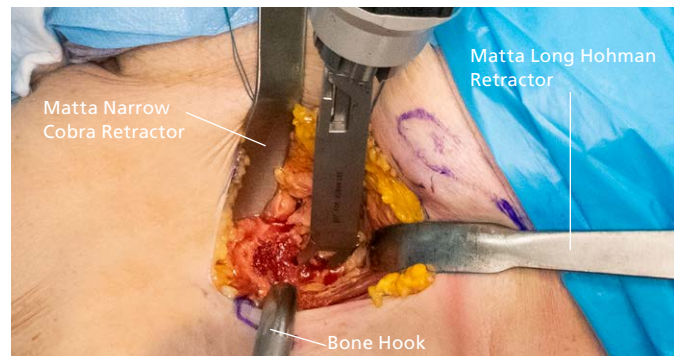


Figure 38b

# Femoral Broaching and Trialing

## Trialing

Place the appropriate trial neck and head onto the broach (Figure 39). Lower the bracket and take out the retractors and femoral hook. Use the table to bring the leg back to neutral position. Pull on the gross traction and internally rotate the leg to reduce the hip.

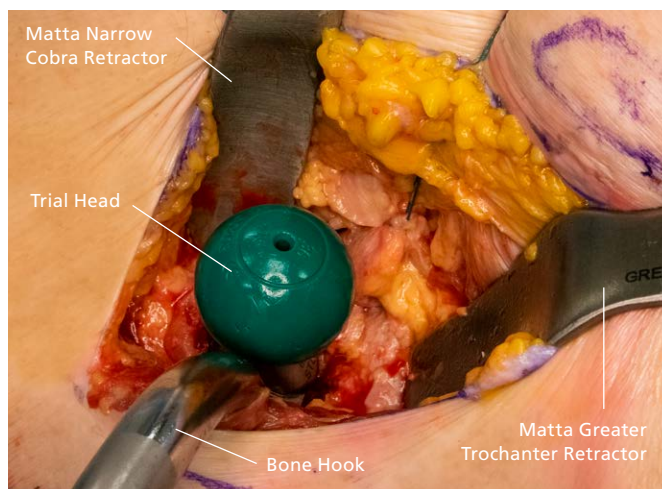


Figure 39

# Femoral Trialing

Check the leg length and offset with the X-ray. Position the hips identically to get accurate comparison views. The table is very helpful for making and holding small adjustments of abduction and rotation to maximize the accuracy of comparison X-rays. Take an X-ray of the non-operative hip to be used as a control. Then take a picture of the operative hip for comparison (Figure 40).

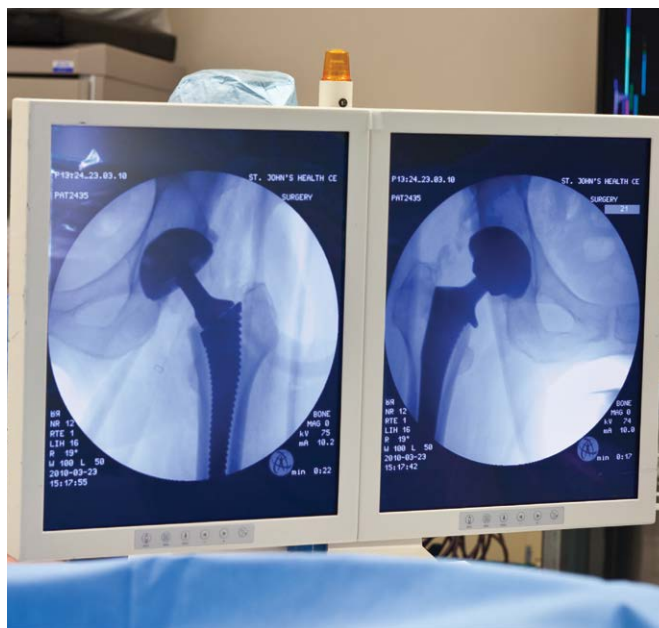


Figure 40

The two X-rays can be printed and overlaid to check femoral offset and leg length. (Figure 41).

**Tip: Take a distal X-ray to check stem direction and correct sizing in the canal.**

The VELYS Hip Navigation System is preferred to "eyeballing" the images as well as the older x-ray overlay technique and has increased accuracy and efficiency for judging leg length and offset. Overlays are done digitally and in most cases comparing the trial hip implants to the pre-neck cut operated hip image. VELYS Hip Navigation can also compare the trial hip implant to the opposite hip and this is preferable if the operated hip requires a significant change in length and offset (e.g. traumatic shortening, CDH, etc.).

**Refer to [VELYSDigitalSurgery.com](http://VELYSDigitalSurgery.com) for VELYS Hip Navigation information.**

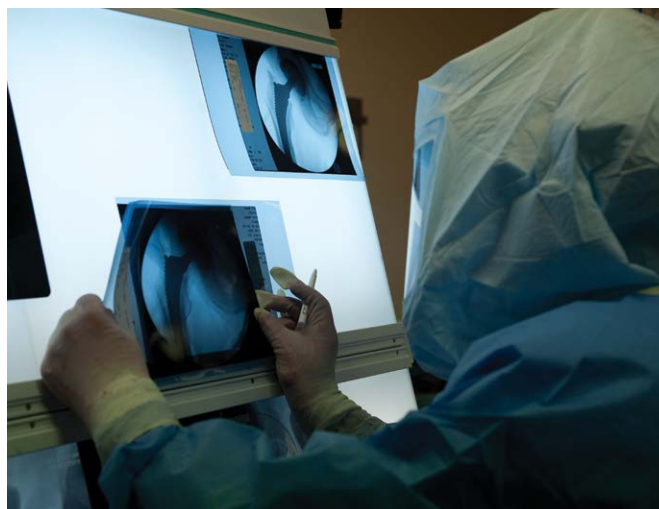

Figure 41

# Final Implantation

Return the femur to the preparation position (dislocate, externally rotate, extend and adduct). Re-establish the femoral exposure with the retractors and elevate the femur with the Bone Hook. If the trial reduction was satisfactory, with good broach size and position, and accurate length and offset, then plane the calcar. Place the MI Calcar Planer (assemble Shaft 2570-04-500 and Mill Disc: 2001-47-000 Small, 2001-48-000 Medium, or 2001-49-000 Large) onto the broach trunion. Mill the calcar to the broach face, allowing the ACTIS Collar to seat flush against the calcar. Make certain the calcar planer is rotating before engaging the calcar to prevent the planer from binding on the calcar.

If during trial reduction it was determined that adjustments were needed, make the necessary adjustments to correct broach size, insertion depth, neck length or offset. Significant adjustments should be checked with another trial.

Gently place the final implant by hand into the prepared canal until no more pressure can be applied

Impact the stem with light blows until it is seated using the Anterior Inserter (2010-07-110, ACTIS Straight Inserter Shaft, 2010-07-120, ACTIS Curved Inserter Shaft, 2598-07-460, Modular Inserter Handle, and 2598-07-440, Bone Preservation Stem Anterior Inserter Shaft). Place the final head onto the stem and impact. The final femoral stem and head implantation can alternatively be performed with the KINCISE Surgical Automated System.

**Refer to the KINCISE System Surgical Brochure found at [KINCISEsystem.com](http://KINCISEsystem.com) for Ordering Information.**

Using the Hana® table, complete the final reduction (Figure 42).

Take a final X-ray, recheck leg length and offset with VELYS Hip Navigation, and perform wound closure by tying the two sutures together and applying irrigation. Close the fascia, subcutaneous tissue and skin.

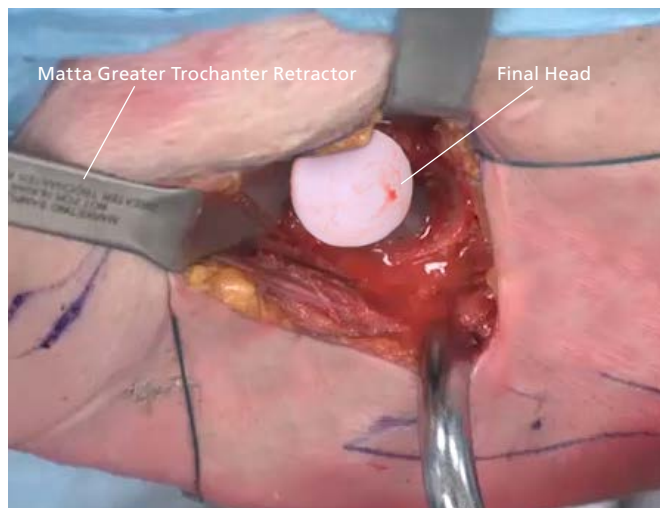


Figure 42



Limited Warranty and Disclaimer: DePuy Synthes products are sold with a limited warranty to the original purchaser against defects in workmanship and materials. Any other express or implied warranties, including warranties of merchantability or fitness, are hereby disclaimed.

Please also refer to the package insert(s) or other labeling associated with the devices identified in this surgical technique for additional information.

CAUTION: Federal Law restricts these devices to sale by or on the order of a physician.

Not all products may currently be available in all markets.

The third party trademarks used herein are the trademarks of their respective owners.

MATTA METHOD™ is a trademark of Joel Matta, MD.

#### References:

1. Barnett SL et al: Is the anterior approach safe? Early complication rate associated with 5090 consecutive primary total hip arthroplasty procedures performed using the anterior approach. J Arthroplasty, 2016; 31(10): 2291-94



**DePuy Orthopaedics, Inc.**  
700 Orthopaedic Drive  
Warsaw, IN 46582  
USA  
Tel: +1 (800) 366-8143  
Fax: +1 (800) 669-2530

© DePuy Synthes 2019, 2020. All rights reserved.  
DSUS/JRC/1117/2477 Rev. 3  
141420-200526 DSUS/EMEA



**Symmetry Medical Manufacturing, Inc.**  
486 W. 350 N. Warsaw, IN 46582-7721, USA  
T. +1 (574) 267-8700

**Johnson & Johnson (NZ) Limited**  
507 Mount Wellington Highway,  
Mount Wellington, 1060  
Auckland, New Zealand

190152-210922 September 2021 NZ