

Special Case Report Series

# JOT

## CASE REPORTS

[www.jorthotrauma.com](http://www.jorthotrauma.com)

# JOURNAL OF ORTHOPAEDIC TRAUMA

**OFFICIAL JOURNAL OF**

**Orthopaedic Trauma Association**

**AO Trauma North America**

**Belgian Orthopaedic Trauma Association**

**Canadian Orthopaedic Trauma Society**

**Foundation for Orthopedic Trauma**

**International Society for Fracture Repair**

**The Japanese Society for Fracture Repair**

# JOT

## CASE REPORT

### Ankle Fractures With Syndesmotic Injury Treated With Distal Fibula Plates and Syndesmotic Fixation Device: A Case Report

*Hector J. Cerón, BS, Luis Guevara, DO, MPH, and Eildar Abyar, MD*

**Summary:** Ankle fractures with concurrent syndesmotic injuries requiring stabilization are prevalent and require immediate care to avoid long-term complications. There are many surgical fixation options for syndesmotic disruption resulting in an ongoing search for the “gold standard.” Standard fixation methods for these ankle injuries are cortical transsyndesmotic screws or suture button constructs. However, technological advances address the disparities within these fixation techniques, which may present several advantages over the aforementioned methods. The present case report aimed to introduce a novel device for syndesmotic fixation and compare this technique with cortical screw and suture button fixation.

**Key Words:** ankle fracture, syndesmotic injury, syndesmotic fixation, cortical screw, suture button fixation

#### INTRODUCTION

The prevalence of ankle fractures with a concurrent syndesmotic injury is approximately 20%.<sup>1</sup> Although syndesmotic injuries can occur in isolation, they are more commonly discovered in conjunction with an ankle fracture or dislocation.<sup>2,3</sup> Disruption of the tibiofibular syndesmosis may cause a diastasis that requires operative treatment to stabilize the ankle. Surgical intervention is necessary to restore the body to its original anatomical composition to avoid long-lasting morbidity. Repercussions of untreated ankle

From the Laredo Physicians Group, Laredo, TX.

The authors report no conflict of interest.

Reprints: Eildar Abyar, MD, 10710 McPherson Rd., Ste. 301, Laredo, TX, 78041 (e-mail: eldar.abiar@gmail.com).

The views and opinions expressed in this case report are those of the authors and do not necessarily reflect the views of the editors of *Journal of Orthopaedic Trauma* or DePuy Synthes.

Copyright © 2022 Wolters Kluwer Health, Inc. All rights reserved.

DOI: 10.1097/BOT.0000000000002492

fractures with syndesmotic injuries include ankle instability and a possibility of early-onset osteoarthritis.<sup>4</sup>

The surgical approach involves using a distal fibula plate to stabilize the fractured bone and tibiofibular ligament, thus maximizing the fibula’s healing process. In this case study, we will be analyzing a novel surgical technique for treating ankle fractures associated with syndesmotic injury. This technique is designed to cohesively aid in the fixation of the ankle and reach the correct anatomical composition. In addition, these techniques offer precision and greater efficiency compared with other forms of surgical intervention, which will later be discussed. Therefore, this case report aimed to discuss ankle fractures associated with syndesmotic injuries treated by using Titanium FIBULINK syndesmosis repair system and Titanium VA LCP distal fibula plates (DePuy Synthes, West Chester, PA).

#### Patient Information

A 49-year-old female patient with morbid obesity presented to an orthopaedic clinic with a history of a right ankle inversion injury associated with immediate pain and swelling of the ankle. The patient complained of a limited, painful range of motion associated with swelling and tenderness to palpation over the lateral and anterolateral ankle joint. The patient was evaluated in the emergency department 1 week prior and was treated conservatively with ice, elevation, immobilization in a short-leg splint, right lower extremity non-weight-bearing with crutches, and was recommended to follow-up with an orthopaedic surgeon. A physical examination demonstrated swelling and ecchymosis over the anterior and lateral aspect of the ankle joint associated with a restricted painful range of motion. In addition, the syndesmosis squeeze test was positive, which generated pain over the anterolateral aspect of the ankle. Radiographic anteroposterior, lateral, mortise, and gravity stress views of the ankle revealed a right lateral malleolus displaced Danis–Weber type B fracture with an increased medial and tibiofibular clear space consistent with syndesmotic injury (Fig. 1). The patient was scheduled for surgery 1 week after the visit and was

told to continue using a short-leg splint and crutches until surgery. The operative plan was to perform a right ankle fracture open reduction internal fixation with syndesmotic repair.

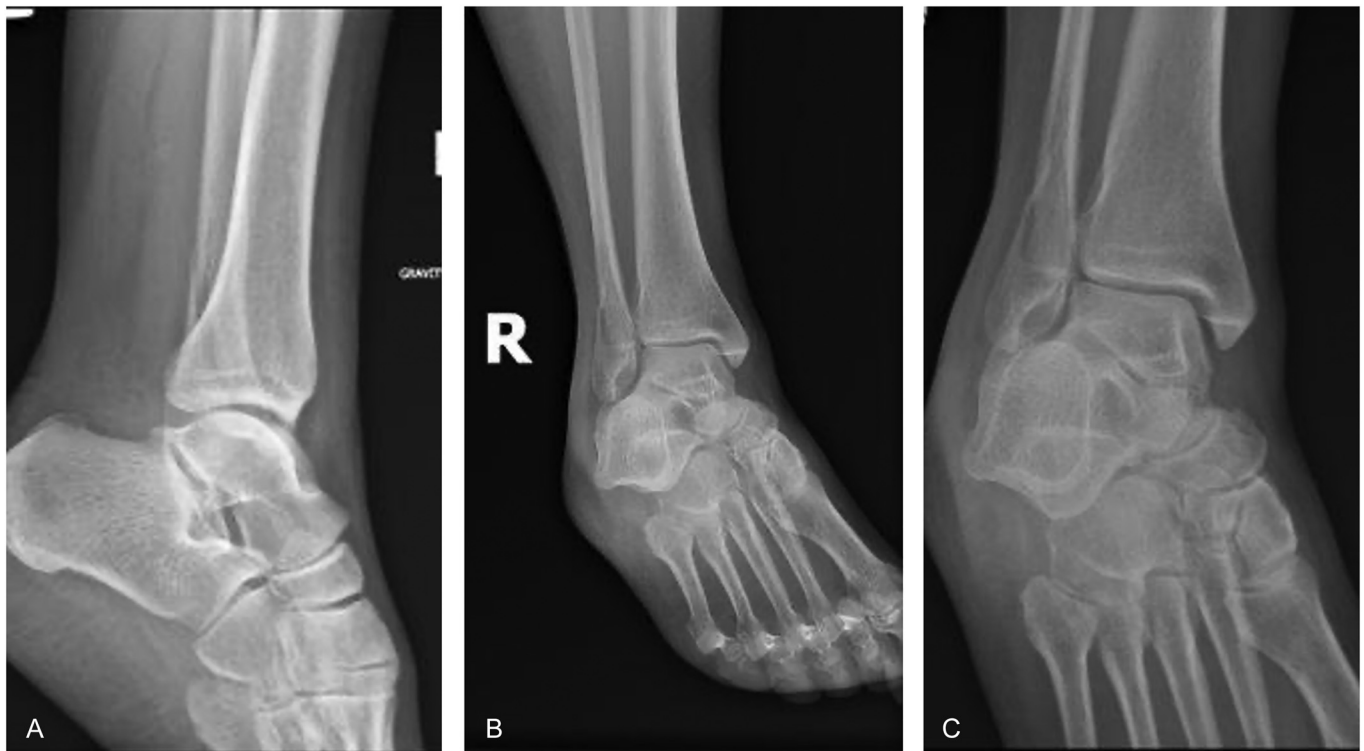
### Surgical Technique

A standard longitudinal, lateral incision was made over the distal fibula, and care was taken to spare overlying nerves and vessels. Dissection was performed to the distal fibula, and an elevator was used to expose the fracture. The fracture was freed of old hematoma and reduced with a clamp. An interfragmentary  $2.7 \times 18$  mm cortical lag screw was placed, and the intraoperative image showed an excellent reduction. The Titanium VA LCP Distal Fibula Plate (DePuy Synthes, West Chester, PA) was then contoured to the lateral malleolus and fixed with cortical screws proximally and cancellous locking screws distally. An anatomic reduction of the distal fibula was obtained with restoration of normal fibular length and alignment (Figs. 2A, B). An intraoperative external rotation stress examination under live fluoroscopy imaging showed a significant increase in medial clear space widening. Therefore, a decision was made to perform syndesmotic fixation. The tibiofibular joint was reduced under fluoroscopic imaging with the reduction clamp. The Kirschner wire (K-wire) was inserted into the fibular plate parallel to the joint line, and then, a step drill bit was used to go through the K-wire. The insertion was performed by using a fluoroscopy-guided technique to follow the screw and ensure it was in the appropriate position. Both drill and K-wire were removed, and the FIBULINK tibial screw was placed. The retention sutures were then taken out from the tibia screwdriver and were removed. The FIBULINK tensioning cap was inserted and was appropriately tightened to achieve ideal reduction, while the silver guide tube was clamped. C-arm fluoroscopy was used to confirm

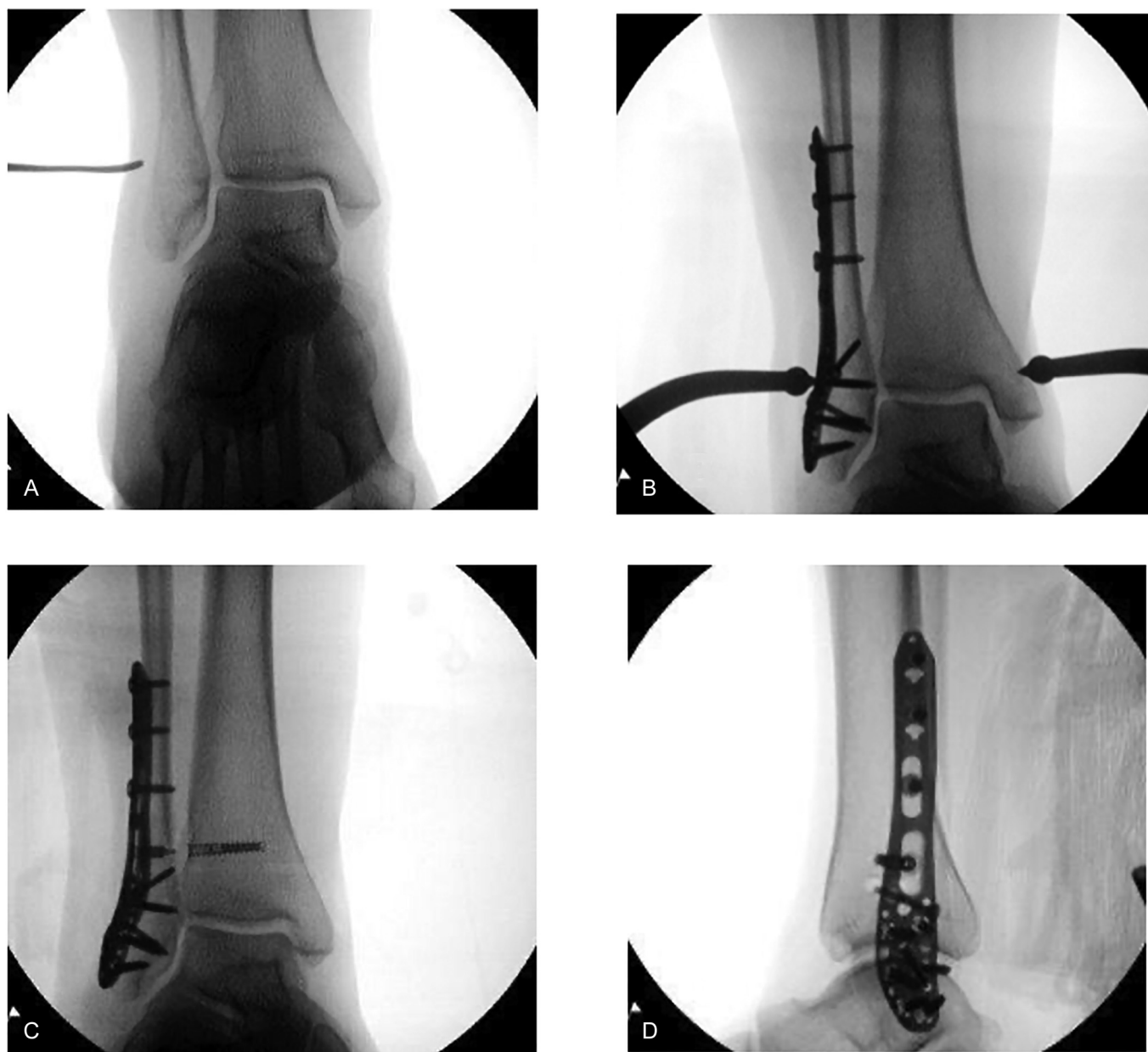
the reduction of the mortise and good placement of all implants with a reasonable length of all screws (Figs. 2C, D). The silver guide tube and the golden lock tube were removed. The incision was closed in layers, and the patient was then placed into a sterile dressing followed by a short-leg splint.

### Postoperative Course

The patient was seen 14 days postoperative and presented with ankle pain (5/10), controlled with pain medications. The patient continued to be non-weight-bearing for 4 more weeks, the dressing and splint were changed, and a short-leg cast was applied. Radiological studies demonstrated decreased medial and tibiofibular clear space, with good alignment and length of the lateral malleolus. At 6 weeks, the cast was removed, and the patient was allowed to weight bear as tolerated. She was instructed to start physical therapy with a gradual return to walking and normal shoe wear with an ASO lace-up ankle brace (Medco Sports Medicine, Warrenton, IL). Radiographic imaging demonstrated good alignment and progressive healing of fracture interval. The following day, the patient started physical therapy. At 3 months, the patient did not have ankle pain at rest but continued having some mild discomfort with walking and with active range of motion of the ankle. As a result, the patient was instructed to continue home exercises and use the lace-up brace as needed. The radiographic findings demonstrated complete fracture interval healing at 3 months with normal medial, tibiofibular clear space of less than 5 mm. At 6 months, the pain was very mild (1/10), and the patient was discharged from physical therapy. The patient was cleared to return to all activities with the exception of high-impact mobility. The radiographic findings showed a completely healed distal fibula fracture and excellent syndesmosis alignment with an absence of implant displacement or



**FIGURE 1.** A, Preoperative lateral radiograph. B, Preoperative oblique image. C, Preoperative anteroposterior image.



**FIGURE 2.** A, Presyndesmosis reduction anteroposterior view. B, Postsyndesmosis reduction anteroposterior view. C, Post-FIBULINK syndesmosis repair anteroposterior view. D, Post-FIBULINK syndesmosis repair lateral view.

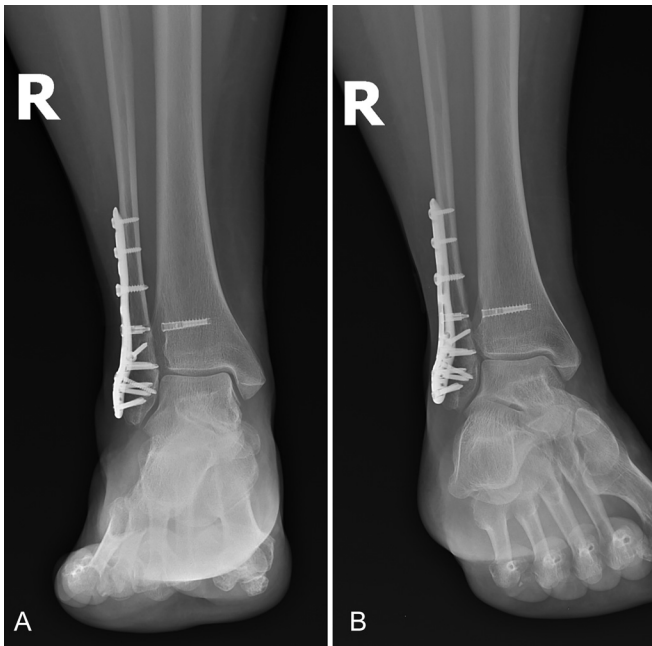
fracture (Figs. 3A, B). The patient was then instructed to follow-up in 6 months for a 1-year follow-up.

### DISCUSSION

Treatment methods for ankle fractures associated with syndesmotic injuries differ based on injury severity. For instance, stable fractures do not typically require surgery, while unstable fractures with ligamentous disruption often require surgical intervention.<sup>5</sup> In addition, if surgical intervention is necessary, an anatomic reduction is essential to avoid functional impairment. Transsyndesmotic screws remain standard for syndesmotic fixation; however, specific issues arise with this technique, including screw breakage which may lead to symptomatic implants requiring surgical removal.<sup>6</sup> For

this reason, the suture button fixation technique was developed, and this fixation evolution resulted in improved physiologic motion for patients postoperatively.<sup>7,8</sup>

Surgeons have long debated which fixation method is best for patients, whether through suture button fixation or with cortical screws; however, an agreement has not been reached.<sup>9</sup> Although uncommon, syndesmotic screw breakage, screw loosening, or stiffness is a possibility when a full-weight-bearing status and normal range of motion activities are resumed.<sup>9</sup> In addition, treating a flexible joint such as the syndesmosis with a rigid screw creates concern for altering normal joint mechanics. This proposed screw fixation disadvantage brought forth the suture button fixation technique.<sup>10</sup> The suture button technique offers semirigid fixation



**FIGURE 3.** A, Anteroposterior and B, oblique postoperative imaging at 6 months.

when stabilizing the syndesmosis and does not withhold basic tibiofibular motion.<sup>11</sup> Nonetheless, some complications have been reported with the suture button technique, such as osteolysis and increased infection caused by the implant.<sup>10,12</sup>

Syndesmosis screw fixation and suture button fixation are popular fixation methods; however, the FIBULINK syndesmosis repair system (Deputy Synthes, West Chester, PA) has several advantages over the previously mentioned techniques. The implant system allows for proper flexibility of the syndesmosis while also providing the fixation of a screw.<sup>10</sup> According to a study conducted on 14 patients who were all treated by using the FIBULINK implant, patients reached favorable results within 9.5 months without the presence of complications.<sup>10</sup> Unlike the cortical screw method, the FIBULINK syndesmosis repair system only requires a single lateral incision, maximizing efficiency and reducing the risk of complications.<sup>11,13,14</sup> The implant system is also the only method of fixation that offers tension control intraoperatively and allows the surgeon to adjust the tension to the desired outcome.<sup>13,14</sup> With this in mind, this form of fixation addresses the drawbacks associated with the traditional forms of syndesmosis repair and is gaining popularity as a reliable method of surgical intervention to treat syndesmosis injuries.

### CONCLUSIONS

Ankle fractures occurring concurrently with syndesmosis injuries are prevalent and should be attended to as soon as possible to avoid future complications. Surgical intervention by using the FIBULINK implant and VA LCP distal fibula plate represents an

effective option for restoring anatomic alignment and maintaining syndesmosis stability. This method of surgical intervention offers the flexibility and stability of various surgical techniques and combines them into 1 system. More research such as prospective randomized trials that compare newer technologies with traditional techniques is needed to measure the long-term results.

### REFERENCES

1. van den Bekerom MPJ, Kloen P, Luitse JSK, Raaymakers ELFB. Complications of distal tibiofibular syndesmosis screw stabilization: analysis of 236 patients. *J Foot Ankle Surg.* 2013;52:456–459.
2. Johnson & Johnson MedTech. FIBULINK™ Syndesmosis Repair System value analysis brief. 2020. Available at: [https://www.jnjmedtech.com/sites/default/files/2022-01/148470-211118\\_D3.1-DPT\\_5410-FIBULINK\\_ValueBrief-Rebrand.pdf](https://www.jnjmedtech.com/sites/default/files/2022-01/148470-211118_D3.1-DPT_5410-FIBULINK_ValueBrief-Rebrand.pdf). Accessed March 4, 2022.
3. Rasmelt S, Obruba P. An update on the evaluation and treatment of syndesmosis injuries. *Eur J Trauma Emerg Surg.* 2015;41:601–614.
4. Rose JD, Flanagan KP, Mlodziński A. Tibiofibular diastasis without ankle fracture: a review and report of two cases. *J Foot Ankle Surg.* 2002;41:44–51.
5. Rasmussen O, Tovborg-Jensen I, Boe S. Distal tibiofibular ligaments: analysis of function. *Acta Orthop Scand.* 1982;53:681–686.
6. van Leeuwen CAT, Hoffman RPC, Hoogendoorn JM. Long-term outcome in operatively and non-operatively treated isolated type B fibula fractures. *Injury.* 2019;50:2318–2323.
7. McKenzie AC, Hesselholt KE, Larsen MS, Schmal H. A systematic review and meta-analysis on treatment of ankle fractures with syndesmosis rupture: suture-button fixation versus cortical screw fixation. *J Foot Ankle Surg.* 2019;58:946–953.
8. Kortekangas T, Savola O, Flinkkilä T, et al. A prospective randomised study comparing TightRope and syndesmosis screw fixation for accuracy and maintenance of syndesmosis reduction assessed with bilateral computed tomography. *Injury.* 2015;46:1119–1126.
9. Shimozone Y, Hurley ET, Myerson CL, et al. Suture button versus syndesmosis screw for syndesmosis injuries: a meta-analysis of randomized controlled trials. *Am J Sports Med.* 2019;47:2764–2771.
10. Bava E, Charlton T, Thordarson D. Ankle fracture syndesmosis fixation and management: the current practice of orthopedic surgeons. *Am J Orthop.* 2010;39:242–246.
11. Desai S *Syndesmosis Repair: 14 Patient Case Series.* Johnson & Johnson Medtech. 2020. Available at: [https://www.jnjmedtech.com/sites/default/files/2021-09/156741-210813%20DSUS%20EMEA\\_Syndesmosis%20Repair%2014%20Patient%20Case%20Series.pdf](https://www.jnjmedtech.com/sites/default/files/2021-09/156741-210813%20DSUS%20EMEA_Syndesmosis%20Repair%2014%20Patient%20Case%20Series.pdf). Accessed March 4, 2022.
12. Naqvi GA, Shafiqat A, Awan N. Tightrope fixation of ankle syndesmosis injuries: clinical outcome, complications and technique modification. *Injury.* 2012;43:838–842.
13. Storey P, Gadd RJ, Blundell C, Davies MB. Complications of suture button ankle syndesmosis stabilization with modifications of surgical technique. *Foot Ankle Int.* 2012;33:717–721.
14. Swords M, Schepers T, Tomlinson M, et al. *FIBULINK Syndesmosis Repair System (aofoundation.org).* 2020. Available at: <https://www.aofoundation.org/approved/approvedsolutionsfolder/2021/fibulink#tab=details> Accessed July 27, 2022.

Read the rest of the **JOT Case Reports** online on [www.jorthotrauma.com](http://www.jorthotrauma.com). It's the Grand Rounds series from the *Journal of Orthopaedic Trauma*, the official journal of the Orthopaedic Trauma Association.