

DR. ADAM WELLIKOFF – JFK MEDICAL CENTER, PALM BEACH, FL

Diagnosis of a 17 mm Right Apical Nodule Following Non-Diagnostic CT-Guided TTNA

Fig. 1

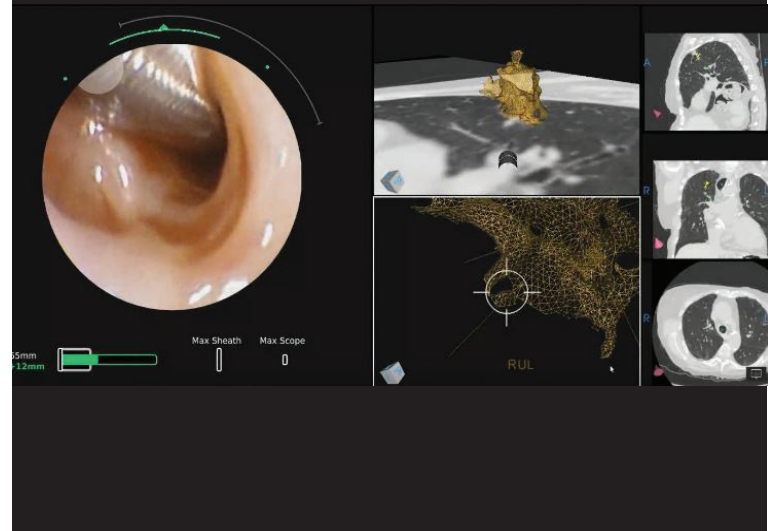


Fig. 2


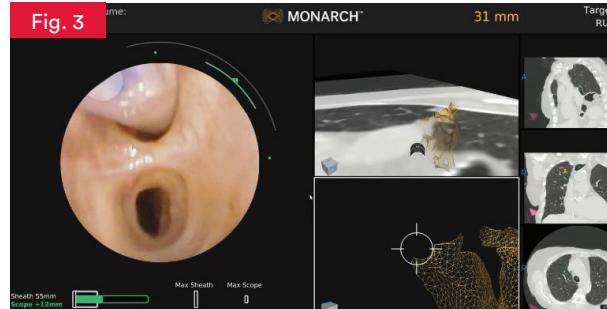


Fig. 3



Background

An 82-year-old female presented with highly symptomatic chronic obstructive pulmonary disease (COPD) was found to have a 17 mm nodule located in the right upper lobe upon CT examination. The patient previously underwent a CT-guided biopsy which came back with non-diagnostic results. Due to the extent of her disease, she was a poor surgical candidate and was referred for a robotic-assisted navigational bronchoscopy.

Planning/Procedure

The MONARCH™ planning software identified a 17 mm nodule located in the apical segment of the right upper lobe that extended medially. Two pathways were planned to the nodule with no definitive bronchus sign leading into the nodule. Within two minutes of navigation the MONARCH™ platform reached the challenging right upper lobe location and REBUS was deployed to confirm positioning for biopsy. (Fig. 1) Initial views showed an eccentric probe position and biopsies were taken which resulted in a non-diagnostic specimen evaluation. Slight adjustments were made with the MONARCH™ Platform using the REBUS probe for guidance until a concentric view was identified. (Fig. 2) A 21G FNA needle and biopsy forceps were used for tissue attainment. (Fig. 3) In room pathology results came back as adenocarcinoma on the second pass with the FNA needle. Once all biopsies were taken, a fiducial marker was deployed in the same area for future therapeutics. The patient was able to begin stereotactic body radiation therapy a week after the procedure within the institution.

Nodule Characteristics

Lobar Location
Right Upper Lobe, Apical Medial

Nodule Size
17 mm

Case Information

Navigation Time (min.)
2:00

Total Procedure Time (min.)
38:00

REBUS: Eccentric to Concentric

Biopsy Tools Used: FNA Needle,
Biopsy Forceps

Final Diagnosis: Adenocarcinoma

Therapeutic Interventions:
SBRT- Fiducial Marker Placed
During Procedure

Fig.1. MONARCH™ fused navigation showing REBUS probe deployment

Fig.2. REBUS Concentric pattern

Fig.3. MONARCH™ screen showing deployment of biopsy tools

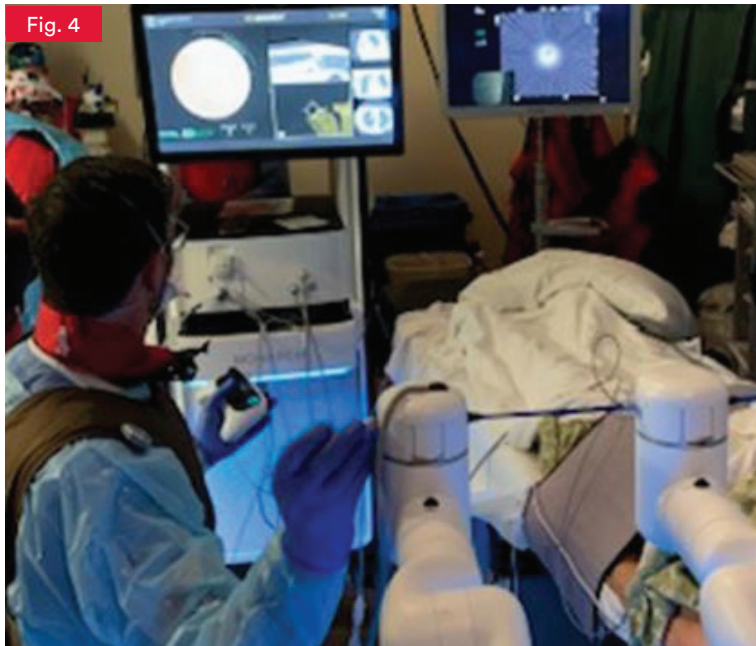



Fig.4. Physician deploying REBUS probe into the MONARCH™ Platform

Conclusion

The precision and control of the MONARCH™ platform allowed for the ability to see the radial probe and make adjustments to biopsy the most accurate location possible. (Fig. 4) Additionally, having the potential to reach challenging locations such as the apical segments after one previous use gives physicians the confidence needed to reach the periphery of the lung. This procedure ultimately led to a quick transition to treatment within the institution even after an unsuccessful previous attempt.

 *The MONARCH™ Platform instills confidence in a physician's ability to reach small lesions in the peripheral lung.*

– Dr. Adam Wellikoff



About Adam Wellikoff, MD

Dr. Adam Wellikoff is a board-certified Interventional Pulmonologist and Critical Care specialist based in Palm Beach, Florida. His clinical interests include advanced diagnostic and therapeutic procedures.

Bronchoscopy Indications for Use: The MONARCH™ Platform and its accessories are intended to provide bronchoscopic visualization of and access to patient airways for diagnostic and therapeutic procedures.

Bronchoscopy Important Safety Statement: Complications from bronchoscopy are rare and most often minor, but if they occur, may include breathing difficulty, vocal cord spasm, hoarseness, slight fever, vomiting, dizziness, bronchial spasm, infection, low blood oxygen, bleeding from biopsied site, or an allergic reaction to medications. It is uncommon for patients to experience other more serious complications (for example, collapsed lung, respiratory failure, heart attack and/or cardiac arrhythmia).

This document reflects the techniques, approaches and opinions of the individual physician. This Ethicon sponsored document is not intended to be used as a training guide. Other physicians may employ different techniques. The steps demonstrated may not be the complete steps of the procedure. Individual physician preference and experience, as well as patient needs may dictate variation in procedure steps. Before using any medical device, review all relevant package inserts with particular attention to the indications, contraindications, warnings and precautions, and steps for use of the device(s).