

DR. SUMMER ALLEN – MEMORIAL HOSPITAL,  
GULFPORT, MS

# Diagnosis of 11 mm Left Lower Lobe Aortic Arch Lesion

Fig. 1

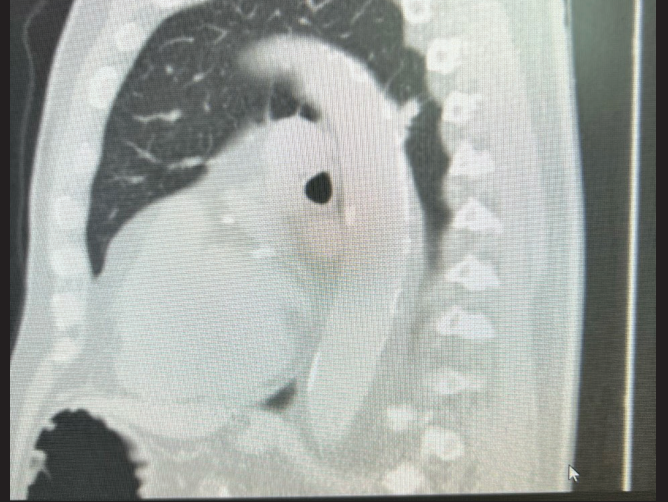

Fig. 2

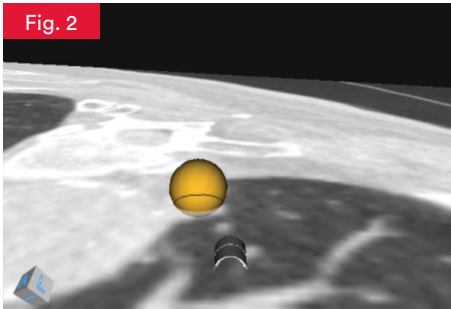



Fig. 3



## Background

A 71-year-old male presented to the hospital through the Low Dose Lung Cancer Screening program with an extensive history of smoking at 45 pack-years. The patient was completely asymptomatic but was advised by his primary care physician to have a screening performed. After the scan, he was found to have an 11.8 mm LLL lesion in the superior segment. (Fig. 1) Further testing with a PET scan showed a mild uptake with an SUV of 5.8. The lesion was in a very high risk location due to abutting the visceral pleura immediately adjacent to the posterolateral wall of the descending thoracic aorta. A CT guided biopsy was not possible due to the location. After further consultation with the patient and risks discussed, the patient elected to have a MONARCH™ Robotic-Assisted Bronchoscopy procedure

## Planning/Procedure

After the initial LDCT, an updated scan was used for pre-procedure planning. Using the sphere mode on the planning software, the nodule was sized to ensure the targeted area was away from the critical structure of the aorta. The plan was saved and imported into the MONARCH™ Platform.

Within minutes of initialization, the lesion was reached while maintaining vision throughout navigation. (Fig. 2) The radial EBUS probe was observed leaving the working channel and entering the airway. Using precise micro-movements with the MONARCH™ scope, the probe was placed in an adjacent airway and the lesion was localized. (Fig. 3) While also using concurrent fluoroscopy and continuous optics, a reference point was made so that the forceps would track directly into the airway that correlated with the concentric rebus signal. This allowed for successful and safe biopsy of the lesion. (Fig. 4) Multiple passes were taken in this area and slides were sent for rapid on-site evaluation. Initial pathology results revealed atypical cells. A bronchi-alveolar lavage was performed along with additional passes for a cellblock. Linear EBUS survey followed which revealed no nodal involvement. The patient had a post-op chest X-ray that showed no signs of pneumothorax or bleeding.

## Nodule Characteristics

Lobar Location  
Left Lower Lobe,  
Superior Segment

Nodule Size  
11.8 mm

## Case Information

Navigation Time (min.)  
4:00

Total Procedure Time (min.)  
52:00

REBUS: Concentric

Biopsy Tools Used: TBBx

Final Diagnosis: Squamous  
Cell Carcinoma

Therapeutic Interventions:  
Surgical Resection

Fig.1. Sagittal CT Image of 11.8 mm Lesion  
Fig.2. MONARCH™ Platform Navigating  
to Target  
Fig.3. Concentric REBUS Image of Lower  
Lobe Lesion

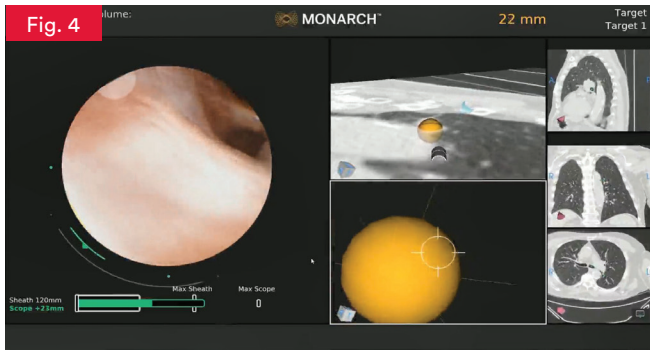



Fig.4. Continuous vision of MONARCH™ Platform

## Conclusion

Final pathology confirmed that this was a squamous cell carcinoma with a negative EBUS. The patient then was evaluated by thoracic surgery and subsequently underwent a robotic resection that showed the lesion was abutting the aorta but not invading the vessel or the pleura. There was no lymph node involvement staging the patient at stage 1A. Thankfully, this patient decided to get a lung cancer screening scan performed due to his extensive smoking history. It most likely saved his life. Moreover, without the capabilities of the robot, this patient would have absolutely been placed into a “watchful waiting” category and his disease would have increased in stage during that time. Vision during biopsy when it matters the most, is absolutely paramount, especially when near critical structures.

 *Due to my confidence in this technology, I was able to safely biopsy this small nodule in a very high risk location. This patient was diagnosed at stage 1 disease and able to have a curative surgical resection. The MONARCH™ Platform has truly transformed our approach to our lung nodule management and thoracic oncology diagnostics at our facility.*

– Dr. Summer Allen



## About Summer Allen, MD

Dr. Summer Allen is a pulmonologist in Biloxi, Mississippi and is affiliated with Memorial Hospital at Gulfport. She received her medical degree from University of Mississippi School of Medicine. She is board certified in Pulmonology Critical Care and Internal Medicine.

Bronchoscopy Indications for Use: The MONARCH™ Platform and its accessories are intended to provide bronchoscopic visualization of and access to patient airways for diagnostic and therapeutic procedures.

Bronchoscopy Important Safety Statement: Complications from bronchoscopy are rare and most often minor, but if they occur, may include breathing difficulty, vocal cord spasm, hoarseness, slight fever, vomiting, dizziness, bronchial spasm, infection, low blood oxygen, bleeding from biopsied site, or an allergic reaction to medications. It is uncommon for patients to experience other more serious complications (for example, collapsed lung, respiratory failure, heart attack and/or cardiac arrhythmia).

This document reflects the techniques, approaches and opinions of the individual physician. This Ethicon sponsored document is not intended to be used as a training guide. Other physicians may employ different techniques. The steps demonstrated may not be the complete steps of the procedure. Individual physician preference and experience, as well as patient needs may dictate variation in procedure steps. Before using any medical device, review all relevant package inserts with particular attention to the indications, contraindications, warnings and precautions, and steps for use of the device(s).